all4maternity
LEARNING • SHARING • CARING

PROFESSIONAL
WEBINAR SERIES

EXAMINATION of the NEWBORN

NIPE WEBINAR SERIES

Series eBook



Forward

Examination of the Newborn eBook content

In this All4Maternity Examination of the Newborn: Professional Webinar Series eBook you can read a series of Chapters that explore newborn care with a focus on the newborn screening examination. The content of each chapter offers an overview and summary to support the content of the webinar series.

The Chapters are brought together from a range of The Practising Midwife journal articles and include an Examination of the Newborn Series.

Enjoy the content.

You can capture your learning, after each article to strengthen your professional development and to inform your engagement in the webinars.



Dr Anna Byrom

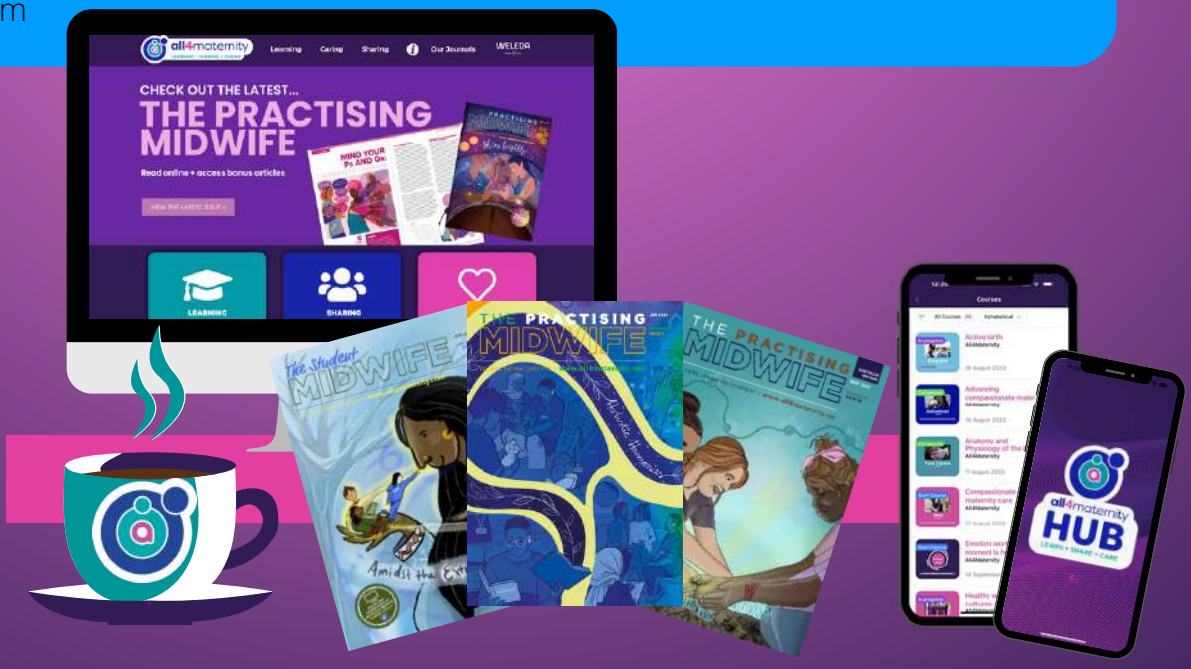

Contents

INTRODUCTION

Connections and Care: Newborn Life Transitions

By Dr Anna Byrom

Newborn and Infant Physical Examination

By Marcia Bartholomew

EXAMINATION OF THE NEWBORN KEY SKILLS

Series by Educators from Birmingham City University

1. **The Eye**
2. **The Cardiovascular system**
3. **The Hips**
4. **The Testes**

NEWBORN CARE PERSPECTIVES

Care close to home: A spotlight on the newborn examination

By Samuel Todd, Dayna Wright, Cathy Green, and Bryony Todd

Decolonising midwifery education: Neonatal assessment

By Diane Mengae, Maxine Chapman, Maureen Raynor,

Zaheera Essat, and Rachel Wells

CONNECTIONS AND CARE: NEWBORN LIFE TRANSITIONS

Dr Anna Coonan-Byrom Midwife, Educator, Researcher, CEO and Founding Director All4Maternity Twitter @ACBMidwife
https://doi.org/10.55975/GHNB3308

The birth of a new life holds significance across all cultures, communities, families and parents. Human newborns, like many infant mammals, are born sentient, learning and expectant of love, nourishment and nurturing relationships.[1] Healthy infants are born with unique adaptations that optimise their survival, prompting care-giving behaviours in their mothers and/or parents.[2] Understanding what neonates need is important to midwives and those caring for families, at birth and in the weeks and months that follow. In this topic highlight, we look at the newborn's sensory needs with a focus on human consciousness, connections and care.

NEWBORN CONSCIOUSNESS

Consciousness can be described as a 'sensory awareness of the body, the self, and the world'.[3] At birth, the newborn's brain is in a transitional stage but is far from empty or inactive.[4] In terms of consciousness, whilst babies may have limited awareness of their body, self and world they are born expecting to hear the heart, sound and scent of their mother or parent. Facilitating immediate and ongoing newborn-mother/parent connection is crucial for enabling optimal transition to life.

NEWBORN CONNECTIONS

Shonkoff and Garner have described an 'ecobiodevelopmental model' to ensure early neonatal care supports life-long health trajectories.[5] This model proposes that ecology becomes biology and together they drive development across the life span. The process of human development is understood as a result of 'nature dancing with nurture over time'.[5] You can see the features of the model, informing neonatal and paediatric care in *Figure 1*.

Figure 1 – Fundamentals of neonatal and paediatric science adapted from Shonkoff and Garner[5]

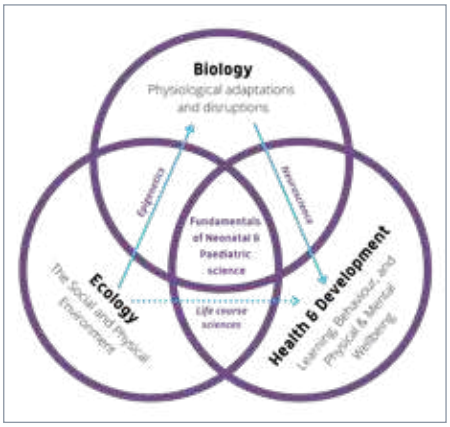

Nils Bergman argues that what the baby needs most at birth is the mother or birthing parent.[1] The mother or parents' body offers environmental (eco) and biological (bio) developmental support to the newborn. As such it is crucial to place the baby in skin-to-skin on the birthing mother or parent's bare chest, ensuring both are covered for warmth. From this position, the newborn develop consciousness: their awareness of themselves and the world around them.

NEWBORN CARE

Beyond birth, ongoing close contact, touch, breastfeeding, positive interactions and communication help to support effective neuro-development, strengthening social development. Midwives, doctors and those caring for newborns should adjust their routine practices ensuring dim lighting, quiet, responsive and personalised care for the infant-mother/parent dyad, respecting harmonious, natural adaptations and transitions. Newborn care based on the ecobiodevelopmental model will ensure the holistic needs of the baby and family are met.

YOU ARE NATURE - WELEDA WISDOM

In 1921, Weleda founders Rudolf Steiner, Ita Wegman and Oskar Schmiedel pioneered a vision for a better future. From the beginning Weleda has centred people, society and nature, setting standards for sustainable, certified natural skincare and anthroposophic medicines based on their understanding of the inseparable connections between human beings and nature.

Calendula is one of the plants that Weleda use to develop natural products to offer protection for delicate, irritated or injured skin. Beyond the newborn period and early days and weeks of life, care should be taken to use treatments and products, as necessary, that are natural and sustainable.

For more information visit www.weleda.com.au

REFERENCES

1. Bergman J, Bergman N. Whose Choice? Advocating Birthing Practices According to Baby's Biological Needs. *J Perinat Educ.* 2013;22(1):8-13. doi:10.1891/1058-1243.22.1.8.

2. Hillman N, Kallaur S, Jobe A. Physiology of Transition from intrauterine to extrauterine life. *Clinic Perinatol.* 2012;39(4):769-783. doi:10.1016/j.clp.2012.09.009.

3. Lagercrantz H, Changeux JP. The Emergence of Human Consciousness: From Fetal to Neonatal Life. *Pediatr Res.* 2009;65:255-260. doi.org/10.1203/PDR.0b013e3181973b0d.

4. Fransson P, Skiold B, Horsch S, et al. Resting-state networks in the infant brain. *Proc Nat Acad Sci U S A.* 2007;104:15531–15536. doi:10.1073/pnas.0704380104.

5. Shonkoff J, Garner A. Technical Report: The lifelong effects of early childhood adversity and toxic stress. *Pediatrics.* 2012;129(1):e232-46. doi:10.1542/peds.2011-2663. Accessed August 11, 2022.

Chapter summary

Key learning points

NEWBORN AND INFANT PHYSICAL EXAMINATION:

MOTIVATING MIDWIVES AFTER 'TRAINING'

Increasingly, the call to incorporate the screening activities of Newborn and Infant Physical Examination (NIPE) as part of the professional remit and the public health role of the midwife has been heeded, illustrated by an increase in the inclusion of the training in both pre-registration and post-registration courses. However, the underutilisation of the skills attained upon completion of training remains evident. Issues that impact on perceptions of empowerment and autonomy in the role may be contributors to the problem. Clear professional boundaries with a focus on low-risk newborns; an increase in the value placed on the extended role, by both midwives and paediatricians; investment in resources that support continuous professional development – could all be an answer to the problem.



> AUTHOR

Marcia Bartholomew
Senior Lecturer in Midwifery at the University of West London

INTRODUCTION

The NHS Newborn and Infant Physical Examination (NIPE) programme is a screening activity usually completed within 72 hours of birth. The detailed examination is primarily performed to confirm that the newborn is healthy, and to identify and refer babies born with congenital abnormalities (Public Health England [PHE] 2018), extending beyond the usual checks made by midwives at birth (Davies 2008; Carr and Foster 2014). By supporting midwives to develop the required clinical competency and knowledge in NIPE, among other benefits, it was seen as a way of empowering midwives and increasing their autonomy (Lomax 2001). However, although a significant number of midwives have undertaken a course to conduct the detailed examination of the newborn, there are some who hesitate to, or have not had

PRACTICE CHALLENGE 1

After completing the training, periodically assess what knowledge and experience you need to enable you to enhance and maintain your competence in performing NIPE skills. Initially it could be at three- or six-monthly intervals, then annually, as you gain experience.

sufficient opportunities to effectively utilise and develop their skills post-qualification (Hayes et al 2003; Rogers et al 2015). This is worrying for a number of reasons: for not only is there a poor return for the investment of time and financial resources (Simms et al 2012), but also midwives are missing vital opportunities to contribute to a public health activity that can hugely impact on the lives of women and their families.

DRIVERS FOR PLACING NIPE IN MIDWIFERY PRACTICE

The bulk of the published work on the midwife's role and involvement in NIPE traversed the developmental pathway from the early 1990s to present day. Documented are the drivers for extending their duties, one of which was the need to improve services to women and their babies by delegating some of the responsibilities of paediatric Senior House Officers (SHOs) to midwives (Department of Health [DH] 1993); reducing doctors' longer working hours to enable compliance with the, then new, European Union Working Time directives. Seemingly reluctant at first, midwives eventually viewed the change as opportunistic, being a means of acquiring new skills and enhancing their range of competencies; and, as implied by MacKeith (1995), fully articulating the lead professional role in the care of women with low-risk pregnancies and birth. Working as part of a multi-disciplinary team in NIPE, it was seen as a way of enabling midwives to further provide health information for women and contribute to the making of policies and protocols which impact on the newborn (Mitchell 2002).

PRACTICE CHALLENGE 2

Think about what would be useful to support you and other NIPE colleagues in developing relevant skills in your local setting. Consider how you can get your ideas moving forward, encouraging peers to join you.

ACCEPTANCE OF MIDWIVES' PRACTICE OF NIPE

In scoping the literature, it would appear that the demands over the years for the skill to be made part of the midwife's role has been heard and acted upon. There is a current increase in the inclusion of NIPE training in pre-registration programmes (Yearley et al 2017). Most of the early studies on the topic – like the seminal report by Townsend et al (2004), often referred to as the EMREN study – were mainly evaluative in their approach. The findings of the work by Townsend et al (2004) have provided a much-needed platform to validate the idea that midwives, when trained, are able to demonstrate competence in undertaking the skill. In one part of this evaluative research, consultant paediatricians rated midwives highly on their performance of NIPE (Bloomfield et al 2003). However, the experienced midwife practitioners who were also observers in this study seemed less satisfied with the accomplishment of their peers.

What women think about midwives performing an examination previously conducted by doctors is important, as it may have implications for the level of respect afforded to their relationship and the perceived value women have of the midwifery profession. However, how fellow paediatricians and midwifery colleagues feel is equally important.

Taking into consideration the findings of the study by Bloomfield et al (2003), it is possible that midwifery practitioners may have unrealistically high expectations of what is necessary during the examination. This could be the consequence of an inherent need to prove themselves in the professional arena, having a need for affirmation of

NIPE AT A GLANCE

NIPE IS A PUBLIC HEALTH ACTIVITY



NEWBORN SCREENING WITHIN 72 HRS OF BIRTH



AIMS TO IDENTIFY AND REFER CONGENITAL ANOMALIES



PART OF THE ENHANCED MIDWIFERY ROLE



NIPE MIDWIVES IMPROVE CONTINUITY



MIDWIVES NEED SUPPORT TO DEVELOP



ONGOING NIPE TRAINING AND UPDATES CRUCIAL



PRACTICE CHALLENGE 3

Consider what learning resources are readily available to you. They should be easy to use and enjoyable to revisit regularly. For example, your favourite midwifery textbook or short, online video clips.

their worthiness, which some may think can only be conferred by them over-performing. If this is so and midwives are too self-critical, it may impact on their belief in themselves and resultant satisfaction in the role, factors which would influence whether they practise NIPE or not.

EMPOWERING NIPE MIDWIVES AND INCREASING THEIR AUTONOMY

In organisations where leadership is empowering, it means that there is a release of resources for learning and development to facilitate experience, so that employees become more competent, enabling them to gain the ability to self-lead and self-manage in practice (Amundsen and Martinsen 2014). Though difficult to define at times, empowerment is closely linked to autonomy and if midwives are to be truly self-governing, effective practitioners, they must feel that they can take, rather than be given, that power to make decisions about their role and their needs for personal development. However, there has been

"If midwives are too self-critical, it may impact on their belief in themselves and resultant satisfaction in the role"





PRACTICE CHALLENGE 4

Continuously reflect on your qualities as a midwife, remembering that a significant portion of the knowledge and skills required in your NIPE role starts with what you already know and do well as a competent midwife.

further research into issues impacting on the expansion of the midwife's duties to include NIPE, exposing recurring themes: a lack of managerial support; non-allocation of resources or protected time for development; feelings of being undervalued; role conflict and crossing over of boundaries, beyond the remit of low-risk pregnancy – have all been cited by midwives as compounding elements (Lumsden 2005; Steele 2007; Simms et al 2012). Certainly, these are essential to improving that sense of motivation, which should occur when empowerment exists. In particular, feelings of appreciation have been looked upon as one of the rudimental features for motivation, to enable individuals to be more productive and achieve their highest potential (Maslow 1943). As healthcare professionals, Maslow's *Hierarchy of needs* (Maslow 1943) is often used to inform how basic care is planned for clients to promote their health. It is equally important to turn the theoretical mirror around, to reflect on how fundamental elements such as respect and acceptance are addressed for NIPE midwives.

> *"It was seen as a way of empowering midwives and increasing their autonomy"*

CONCLUSION

It seems that the analogy of a train running full steam ahead is apt here. Over the last two decades, midwives have been invited to take a journey, with a promise of professional rewards such as increased autonomy, empowerment, an improved service for women and their babies. However, there needs to be a continuous focus on the experiences of midwives as passengers on this journey or what will happen to the new travellers that come on board; particularly those qualifying through pre-registration midwifery programmes. Midwives appear not to be fully satisfied with the ride, with some disembarking as soon as they board and not wanting to get back on. Lacking feelings of fulfilment and perception of support, for many correlate to a number of factors, including clearer demarcation of roles and responsibilities. Working as part of the multidisciplinary team is pivotal to the effectiveness of service, but the remit of midwives as experts in low-risk pregnancy and birth must not be forgotten. Factors that influence how contented NIPE midwives feel, such as the resources available for continuous professional development, may be one of the answers to provide encouragement for them to use their valuable NIPE skills. **TPM**



> *"It was seen as a way of enabling midwives to contribute to the making of policies and protocols which impact on the newborn"*

REFERENCES

Amundsen S and Martinsen ØL (2014). 'Empowering leadership: construct clarification, conceptualization, and validation of a new scale'. The Leadership Quarterly, 25(3): 487-511.

Bloomfield L, Rogers C, Townsend J et al (2003). 'The quality of routine examinations of the newborn performed by midwives and SHOs; an evaluation using video recordings'. Journal of Medical Screening, 10(4): 176-180.

Carr N and Foster P (2014). 'Examination of the newborn: the key skills. Part 1. The eye'. The Practising Midwife, 17(1): 26-29.

Davies L (2008). 'Examination of the newborn: a holistic approach'. The Practising Midwife, 11(4): 24.

DH (1993). Changing childbirth: report of the expert maternity group, London: HMSO.

Hayes J, Dave S, Rogers C et al (2003). 'A national survey in England of the routine examination of the newborn baby'. Midwifery, 19(4): 277-284.

Lomax A (2001). 'Expanding the midwife's role in examining the newborn'. British Journal of Midwifery, 9(2): 100-102.

Lumsden H (2005). 'Midwives' experience of examination of the newborn as an additional aspect of their role: a qualitative study'. MIDIRS Midwifery Digest, 15(4): 450.

MacKeith N (1995). 'Who should examine the 'normal' neonate?' Nursing Times, 91(14): 34-35.

Maslow AH (1943). 'A theory of human motivation'. Psychological Review, 50(4): 370.

Mitchell M (2002). 'The neonatal examination. A chance to provide health education and influence public health'. The Practising Midwife, 5(5): 32.

PHE (2018). Newborn and Infant Physical Examination Screening Programme Standards, London: PHE.

Rogers C, Jay A, Yearley C et al (2015). 'National survey of current practice standards for the newborn and infant physical examination'. British Journal of Midwifery, 23(12).

Simms M, Mitchell S and Choucri L (2012). 'Seamless service?' Midwives, 3: 48-49.

Steele D (2007). 'Examining the newborn – why don't midwives use their skills?' British Journal of Midwifery, 15(12): 748-752.

Townsend J, Wolke D, Hayes J et al (2004). 'Routine examination of the newborn: the EMREN study. Evaluation of an extension of the midwife role including a randomised controlled trial of appropriately trained midwives and paediatric senior house officers'. Health Technology Assessment, 8(14): iii-iv.

Yearley C, Rogers C and Jay A (2017). 'Including the newborn physical examination in the pre-registration midwifery curriculum – national survey'. British Journal of Midwifery, 25(1): 26-32.

Chapter summary

Key learning points

EXAMINATION OF THE NEWBORN: THE KEY SKILLS

1. THE EYE



SUMMARY

Performing the newborn and infant physical examination (NIPE) is now recognised as part of the midwife's sphere of practice. The majority of higher education institutions currently provide, or plan to include, NIPE training into their pre-registration curricula[1] and many qualified midwives are embracing the NIPE role through undertaking continuous professional development modules.[2] In the first of a five-part series, this article considers the importance of the eye examination in the screening process. The significance of history taking, knowledge of risk factors and the detection of the red reflex will be explored. The necessity for early detection of congenital cataracts, retinoblastoma and glaucoma, and the prerequisite referral pathways that the examination requires will also be highlighted.

> AUTHORS



Ruby Handley-Stone
Midwifery Lecturer, Birmingham City University

Paola Armato-Harris
Midwifery Lecturer, Birmingham City University

Natasha Carr
Senior Lecturer in Midwifery and Course Lead in Midwifery, Birmingham City University

Samantha Meegan
Senior Midwifery Lecturer, Birmingham City University

Samuel Todd
Midwifery Lecturer, Birmingham City University
Twitter @BCUMidwives

INTRODUCTION

A detailed clinical examination is required as part of the national screening programme. Undertaken within 72 hours of birth, this examination encompasses screening for congenital cardiac defects, developmental dysplasia of the hip, congenital cataracts and cryptorchidism, as well as a robust, holistic examination.[3]

Midwives are responsible for ensuring that they are, and remain, competent to carry out any aspect of their professional role,[4] including universal care for all women and newborn infants. They are expected to carry out an appropriate number of examinations to maintain quality and retain the necessary skills.[3] As such, it is widely recognised that midwives are the most appropriate healthcare professionals to conduct the NIPE on low-risk infants.[5,6] Evidence has clearly demonstrated the clinical effectiveness of the midwife undertaking this examination, with increased parental satisfaction[7,8] and the ability to provide continuity of care to women and their families.

Obtaining informed parental consent before the examination of the newborn is essential[9] and not limited simply to permission seeking. Midwives should explain to parents that some physical conditions might become evident at a later stage, with screening taking place again through another comprehensive examination at six to eight weeks after birth.[3]

DEVELOPMENT OF THE EYE

The development of the eye occurs between week three and week six of gestation, with the ocular structures and brain well organised by week six. For normal vision to occur, many complex structures within the eye must develop in relation to each other. The cornea and lens must both become transparent and properly aligned to allow a pathway for light to reach the retina[10] (see *Figure 1*).

***Figure 1* Anatomy of the eye**

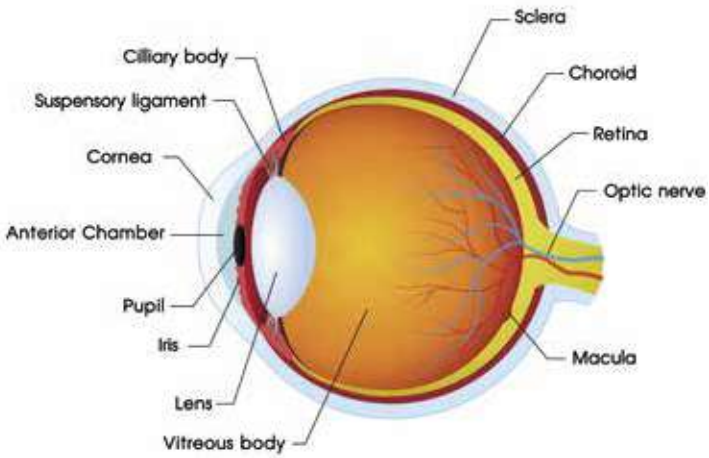

Development of the eye persists beyond birth, with myelination of the visual pathway not completed until two years of age.[11] Any disruption to the process of this visual development may threaten the sight of the baby or infant.

EXAMINATION OF THE EYE

The purpose of the NIPE newborn and infant eye screening examination is to detect any eye abnormality which may threaten the life or sight of the baby, with the primary purpose to identify congenital cataracts. Around two to three in every 10,000 babies are born with cataracts,[3] and this is the most common treatable cause of blindness in the UK.

Risk factors

***Table 1* Risk factors for eye problems**[3]

Prematurity
Genetic syndromes associated with eye disorders, such as Trisomy 21
A first-degree relative with an ocular condition that was congenital or developed in early childhood, such as congenital or hereditary cataracts, aniridia, coloboma or retinoblastoma

In addition to the risk factors for eye problems shown in *Table 1*, there are also other factors that the midwife must be alert to, which she may have identified from her review of the history, such as low birthweight or low gestational age[11] and ocular teratogens (see *Table 2*).

***Table 2* Ocular teratogens**[12]

Teratogen	Ocular implications in newborn
Alcohol	Coloboma, cataract, nystagmus
Opioids	Nystagmus, reduced vision
Cocaine	Prolonged eyelid oedema, optic nerve abnormalities
Vitamin A	Microphthalmia, hypertelorism
Rubella	Cataract, glaucoma, microphthalmos
CMV/HSV	Cataract, microphthalmos, chorioretinitis
Syphilis	Cataract, glaucoma
Anticonvulsants	Myopia, prominent long eyelashes
Diabetes mellitus	Optic nerve hypoplasia

Prior to any physical examination, the midwife should ascertain the medical, family, antenatal, intrapartum and neonatal history, and also enquire about any parental concerns.[3] In particular, any history of hereditary eye problems should be identified.

Observation

General observation of the newborn eyes would include any trauma, bruising, petechiae, birthmarks, oedema or discharge. Some will spontaneously resolve; others, such as port-wine nevi involving the eyelid, can be associated with Sturge-Weber syndrome and will require referral. The eyes should be observed for position, size and symmetry. The eyes should be positioned symmetrically in the front of the face. Widely spaced eyes (hypertelorism) or small eyes (microphthalmia) may be suggestive of a syndrome. Eyes that appear large are associated with congenital glaucoma.[13] Presence of the normal features of the eye such as eyelids, eyelashes and eyebrows should be confirmed. Any drooping of the eyelid (ptosis) may indicate a weakened or absent eyelid muscle or a subtle clinical sign of disease elsewhere.[14] Ptosis warrants an immediate referral, as it poses a significant threat to the normal development of the baby's sight. Epicanthic folds are associated with Down's syndrome but can also exist as a normal variant or associated with ethnic groups. Epicanthic folds alone should not be considered a diagnostic indicator for Down's syndrome.

The open eye should be examined for the presence of the cornea, iris and sclera. The colour of the sclera should be noted: the sclera is bluish-white in the newborn, and any yellowing may indicate jaundice; an unusual blue colouring of the sclera is seen in a variant of osteogenesis imperfecta. The position and movement of the eyeball should be examined. Abnormal eye movements and any strabismus (squint) which appears to be fixed should be referred to an appropriate specialist.[13]

Inspection

The eye examination is completed using the ophthalmoscope, an instrument designed to examine the structure of the eye.

> *It is widely recognised that midwives are the most appropriate healthcare professionals to conduct the NIPE on low-risk infants*



> *The purpose of the NIPE newborn and infant eye screening examination is to detect any eye abnormality which may threaten the life or sight of the baby*

The room should be darkened so that the pupils will enlarge (mydriasis), with the baby settled and encouraged to open its eyes naturally. Consideration should be given to changing the baby from supine to upright, with auditory stimulus to encourage this. The eyelids may be gently parted, if necessary, however forcefully prising the eyelids open may cause the eyelids to evert and hinder accurate visualisation.[13] In addition, through prising open eyelids, clinicians increase the risk of neonatal conjunctivitis due to the lack of immunity and absence of lymphoid tissue at birth.[15] The midwife will then need to examine the eyes for the red reflex, which is the red glow in the pupil zone due to light scattered from the vascular choroid layer. The purpose of the red reflex test is to detect abnormalities of the retina, the lens and the cornea.[16] The ophthalmoscope lens should be set to '0' and the largest aperture selected. The ophthalmoscope should be positioned close to the operator's eye, at arm's length from the baby's face.[3]

Normal red reflex

The red reflex should appear in the baby's pupil (see *Figure 2*), with both reflexes seen simultaneously. If the aperture does not allow visualisation of both reflexes at once, then altering your distance backwards until you can observe both red reflexes should be undertaken. Red reflexes should appear clear and equal in colour and intensity in each eye. If a clear red reflex is not seen in one or both eyes, they should be examined individually and compared.

***Figure 2* Normal and abnormal appearance of the eye**

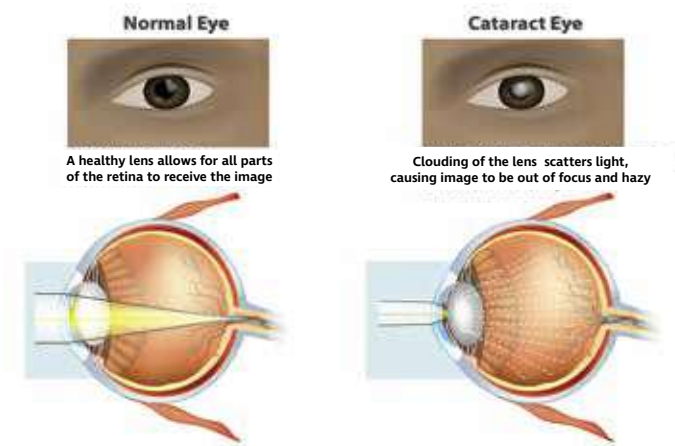

Further examination required

A referral is warranted if the examination shows:

- A white pupillary reflex (leukocoria), which could indicate a retinoblastoma (see *Figure 2*)
- The presence of opacities in the reflex, which could indicate a cataract
- The absence of any reflex
- Inequality in colour, intensity or clarity of the reflection.

Screeners should be aware that the normal red reflex varies depending on the baby's ethnicity, appearing less bright and magnolia in colour in Black, Asian or minority ethnic babies. In this instance, it is advisable to cross-examine the baby's parents' red reflex in order to determine the expected reflex colour.[3]

Retinoblastoma

Retinoblastoma is a life-threatening ocular condition, occurring in about one per 18,000 live births,[17] with around 50–60 children newly diagnosed each year in the UK.[18] There are two forms of retinoblastoma – an inheritable (often bilateral) and a non-inheritable form (usually unilateral). In the inheritable form, the dominant abnormal gene may either be inherited from a parent or occur for the first time at an early stage of eye development. Whilst children are likely to survive this cancer, many will suffer consequences from a delayed diagnosis, including the loss of one or both eyes, poor sight or blindness. Therefore, staff must be vigilant to the signs to achieve a prompt diagnosis.[19]

Congenital cataract

The UK incidence of congenital cataract rates ranges from two to three per 10,000 of the population by age one.[3,20] A cataract is an opacification of the lens of the eye; often associated with systemic anomalies in children, causing 20% of childhood blindness worldwide and requires prompt surgery if sight is to be preserved.[21] Midwives are recognised as having a significant role in helping to prevent profound amblyopia if early detection and management is exercised.

Congenital glaucoma

Congenital glaucoma affects only 0.05% of newborn babies,[22] however has been blamed for 5% of childhood blindness worldwide.[23] Glaucoma is fundamentally a problem of improper drainage of fluid in the eye as a result of incorrect or poor development before birth. The raised intraocular pressure is thought to damage the optic nerve resulting in vision loss[16] but, if the pressure is well-controlled through surgical management, vision can be improved. The aetiology of congenital glaucoma is not fully understood, with most cases being sporadic (no family history), however about 10–40% are familial, with an autosomal recessive inheritance pattern.[24] Additionally, congenital glaucoma appears most prevalent in ethnic groups with high rates of consanguineous marriages.[25,23]

Referral

Following the examination, any abnormalities should be referred according to Public Health England's[3] pathways in *Table 3*. In addition to the referral pathways stated below, if the midwife is concerned in any way, it is advised that the examination is repeated by another experienced practitioner within the 72-hour guideline period.

MESSAGES FOR MIDWIVES

The examination of the eye should not be considered in isolation, as it is only one aspect of the wider holistic examination of the newborn, with parents and their baby remaining at the centre of care. The importance of the midwife's role cannot be overstated. Ensuring effective history taking related to hereditary eye problems, early recognition, ensuring precision of red reflex examination, good record-keeping and prompt referral along the correct pathways will ensure optimal treatment to prevent long-term negative sequelae for children. **TPM**

***Table 3* The NHS newborn and infant physical examination programme (NIPE) referral pathway for examination of the eye[3]**

Findings	Action		
• No risk factors • Negative screen	Repeat at 6–8 weeks by a trained healthcare professional		
• Positive risk factors • Negative screen	Expert opinion within 72 hours of birth	If positive	Seen by ophthalmic consultant within 2 weeks of the screening examination being performed
		If negative	6–8-week screening
• Positive/ negative risk factors • Positive screen	Expert opinion within 72 hours of birth	If positive	Seen by ophthalmic consultant within 2 weeks of the screening examination being performed. If concerns, seen prior to discharge home
		If negative	6–8-week screening

FIVE PRACTICE PARTNER POINTS

1. Further your knowledge by completing Unit 2 'Screening examination of the eyes' of the NHS Newborn and Infant Physical Examination e-learning programme.
2. Did you know that guidance regarding the distance in which the ophthalmoscope should be held from the newborn's face has only recently changed? Examine the conflicting evidence and guidance with wider reading.
3. Develop your clinical experience by following a newborn with a positive screening outcome through the referral process – can you shadow a consultant ophthalmologist for the day?
4. Make a note of your experience in identifying the red reflex presenting in babies of non-Caucasian ethnicities. How many variations of the reflex have you seen?
5. Reflect on your experience in identifying complex conditions associated with the eyes. Have you been able to successfully identify conditions such as glaucoma? How did it present?



"The eye examination is completed using the ophthalmoscope, an instrument designed to examine the structure of the eye"

REFERENCES

1. Nursing and Midwifery Council (2019) Standards for pre-registration midwifery programmes. London: NMC.

2. Yearley C, Rogers C, Jay A. Including the newborn physical examination in the pre-registration midwifery curriculum: National survey. Br J Midwifery. 2017;25(1):26-32.

3. Public Health England. Newborn and infant physical examination (NIPE) screening programme handbook. https://www.gov.uk/government/publications/newborn-and-infant-physical-examination-programme-handbook/newborn-and-infant-physical-examination-screening-programme-handbook. Updated April 28, 2021.

4. Nursing and Midwifery Council. Standards of proficiencies for midwives. https://www.nmc.org.uk/globalassets/sitedocuments/standards/standards-of-proficiency-for-midwives.pdf. Published November 18, 2019.

5. Rogers C, Jay A, Yearley C, Beeton K. National survey of current practice standards for the newborn and infant physical examination. Br J Midwifery. 2015;23(12):862-873.

6. Fryer N, Evans C. Examination of the newborn: professional issues in practice. In: Lomax A, ed. Examination of the Newborn: An Evidence-Based Guide. Chichester: Wiley-Blackwell; 2015:213-238.

7. Osborne K. Are specially trained midwives the right professionals to perform the newborn physical examination? Br J Midwifery. 2017;25(3):174-179. doi:10.12968/bjom.2017.25.3.174.

8. Townsend J, Wolke D, Hayes J, et al. Routine examination of the newborn: the EMREN study. Evaluation of an extension of the midwife role including a randomised controlled trial of appropriately trained midwives and paediatric senior house officers. Health Technol Assess. 2004;8(14):iii-100. doi:10.3310/hta8140.

9. Nursing and Midwifery Council (2018). Professional standards of practice and behaviour for nurses, midwives and nursing associates. London: NMC.

10. Carlson, B. Human Embryology and Developmental Biology. 6th ed. Philadelphia: Elsevier. 2018.

11. Noonan C, Rowe FJ, Lomax A. Chapter 4: Examination of the head, neck and eyes. In: Lomax A, ed. Examination of the Newborn: An Evidence-Based Guide. 3rd ed. Chichester: Wiley-Blackwell. 2021:93-112.

12. Tandon A, Mulvihill A. Ocular teratogens: old acquaintances and new dangers. Eye (Lond). 2009;23(6):1269-1274. doi:10.1038/eye.2009.30.

13. Tappero EP, Honeyfield ME. Physical Assessment of the Newborn: A Comprehensive Approach to the Art of Physical Examination. 6th ed. New York, NY: Springer Publishing Company. 2019.

14. Patel K, Carballo S, Thompson L. Ptosis. Dis Mon. 2017;63(3):74-79. doi:10.1016/j.disamonth.2016.10.004.

15. McAnena L, Knowles SJ, Curry A, Cassidy L. Prevalence of gonococcal conjunctivitis in adults and neonates. Eye (Lond). 2015;29(7):875-880. doi:10.1038/eye.2015.57.

16. James B, Bron A. Opthalamology Lecture Notes. 11th ed. Chichester: Wiley-Blackwell. 2011.

17. Fabian ID, Sagoo MS. Understanding retinoblastoma: epidemiology and genetics. Community Eye Health. 2018;31(101):7.

18. Implications of Retinoblastoma for children. Royal National Institute of Blind People. https://www.rnib.org.uk/insight-online/implications-retinoblastoma-children. Updated February 23, 2018.

19. Maxwell P. Identifying signs of retinoblastoma. Nursing Times. 2013;109(28):17.

20. Rahi JS, Dezateux C; British Congenital Cataract Interest Group. Measuring and interpreting the incidence of congenital ocular anomalies: lessons from a national study of congenital cataract in the UK. Invest Ophthalmol Vis Sci. 2001;42(7):1444-1448.

21. Allen LE. Childhood cataract. Pediatr Child Health. 2020;30(1):28-32.

22. Aponte EP, Diehl N, Mohney BG. Incidence and clinical characteristics of childhood glaucoma: a population-based study. Arch Ophthalmol. 2010;128(4):478-482. doi:10.1001/archophthalmol.2010.41.

23. Yu-Wai-Man C, Arno G, Brookes J, Garcia-Feijoo J, Khaw PT, Moosajee M. Primary congenital glaucoma including next-generation sequencing-based approaches: clinical utility gene card. Eur J Hum Genet. 2018;26(11):1713-1718. doi:10.1038/s41431-018-0227-y.

24. Weinreb RN, Grajewski A, Papadopoulos M, Grigg J, Freedman S. Childhood Glaucoma: the 9th consensus report of the World Glaucoma Association. Netherlands: Kugler Publications. 2013.

25. Khan MU, Zia MUQ, Tabassum W. An Insight into Primary Congenital Glaucoma. Crit Rev Eukaryot Gene Expr. 2020;30(1):39-43. doi:10.1615/CritRevEukaryotGeneExpr.2020027901.

Chapter summary

Key learning points

EXAMINATION OF THE NEWBORN: THE KEY SKILLS

2. THE CARDIOVASCULAR SYSTEM AND CONGENITAL HEART DISEASE



SUMMARY

Many midwives conduct the holistic examination of the newborn prior as part of routine midwifery care. In this second article of a five-part series, consideration is given to the importance of the cardiovascular examination during the screening process. The significance of history taking, risk factors and the process of the cardiac system examination are discussed. The prerequisite referral pathways within the newborn infant physical examination (NIPE) screening programme are explored.

> AUTHORS



Samantha Meegan
Senior Midwifery Lecturer, Birmingham City University

Paola Armato-Harris
Midwifery Lecturer, Birmingham City University

Natasha Carr
Senior Lecturer in Midwifery and Course Lead in Midwifery, Birmingham City University

Ruby Handley-Stone
Midwifery Lecturer, Birmingham City University

Samuel Todd
Midwifery Lecturer, Birmingham City University
Twitter @BCUMidwives

INTRODUCTION

Screening for congenital heart disease (CHD) forms part of the systematic newborn infant physical examination, known as NIPE, within England. Assessment of the cardiovascular system is an important element in the examination but is not isolated from other aspects of the holistic examination.[1] Early detection and diagnosis of CHD ensures appropriate and timely treatment. CHD can be described as a heart condition resulting from an abnormality of the structure or function of the heart present from birth.[2]

TIMING OF THE EXAMINATION

In the United Kingdom (UK), screening for CHD forms part of the NIPE, including examination of the eyes, heart, hips and testes, within male newborns. The NIPE is first performed within 72 hours of life and repeated at six to eight weeks of age.[3]

Early detection of CHD improves the mortality and long-term morbidity of the infant[3]; however there is evidence to suggest that fewer than half of all CHDs present at birth are detected during the newborn examination.[4,5] Some critical and major cardiac lesions are detected in the antenatal period as part of the NHS Fetal Anomaly Screening Programme (FASP) during the 20-week ultrasound scan. The FASP target detection rate for cardiac abnormality is 50%.[3]

The timing of when the cardiovascular examination should take place has long been debated.[4,5,6] Historically, cardiac examination was delayed for 24 hours to allow for the physiological changes within the baby to take place,[7] and for duct-dependant, critical congenital heart defects to manifest.[8] The literature does not support this, hence the timing of cardiac auscultation appears to be based on custom and practice. The UK National Screening Committee (UK NSC) provides no optimal time to detect abnormalities; however it's acknowledged that the risk of discharging babies unscreened is greater than conducting early screening.[9]

Examining the newborn is critical for recognising difficulties in transition to extrauterine life.[10] The newborn infant's cardiovascular system undergoes many adaptations following birth and a single examination may not pick up all defects.[6] Closure of the ductus arteriosus, for example, may not occur until two to seven days of age.[11,12] Parents and carers should be advised that their baby's cardiovascular system is still transitioning following birth, and that it is possible that heart murmurs could be heard on auscultation, especially if these changes are still taking place around the time of the examination.[13] They should be advised that the absence of a murmur does not rule out the presence of CHD,[3] and must receive information regarding signs and symptoms of CHD, as well as advice regarding action to be taken if concerns arise.

FETAL TO NEONATAL CIRCULATION

The transition from fetal to neonatal life requires closure of temporary circulatory shunts, which are the ductus venosus, ductus arteriosus and foramen ovale. At birth the clamping of the cord results in the termination of the blood flow through the ductus venosus. The result is increased systemic vascular resistance in the newborn.[14] When the baby takes its first breath, the pulmonary vessels respond to the increase in the oxygen content of the blood by vasodilation. This reduces pulmonary vascular resistance and encourages blood to flow to the lungs; blood then returns to the left side of the heart. After birth the pressure in the left side of the heart increases, as the pressure in the right side decreases. These pressure changes force the flap of the foramen ovale to close, which forms the two separate atriums. The ductus arteriosus closes in response to increases in oxygen levels and a reduction in prostaglandins.[15]

THE EXAMINATION

Purpose

The purpose of the cardiovascular examination is to detect life-threatening congenital cardiac anomalies. Babies may have structural defects or may simply be experiencing a delay in the transition to extrauterine life.

Incidence

The overall incidence of CHD from non-significant to major and critical lesions ranges from six to twelve per 1,000 live births.[3] Critical congenital heart disease (CCHD) accounts for approximately 15–25% of these, and includes all potentially life-threatening duct-dependent conditions and conditions which require treatment within the first 28 days of life.[3] Other defects, including defects not classified as critical but requiring invasive intervention in the first year of life, are categorised as major serious CHD.

Risk factors

Congenital cardiac disease is multifactorial, hence a combination of factors is considered during assessment of the baby (see *Box 1*).

Box 1 Risk factors for congenital cardiac problems[3]

- Family history of CHD (first-degree relative)
- Fetal trisomies, such as Trisomy 21
- Cardiac abnormality suspected from the antenatal scan
- Maternal exposure to viruses during pregnancy
- Maternal conditions, such as diabetes (type 1), epilepsy systemic lupus erythematosus (SLE)
- Exposure to teratogenic drugs during pregnancy



> *"Parents and carers should be advised that their baby's cardiovascular system is still transitioning following birth, and that it is possible that heart murmurs could be heard on auscultation, especially if these changes are still taking place around the time of the examination."*[13]

> *The purpose of the cardiovascular examination is to detect life-threatening congenital cardiac anomalies. Babies may have structural defects or may simply be experiencing a delay in the transition to extrauterine life.*

Involving parents

Prior to any physical examination, the midwife should enquire about any parental concerns and obtain informed consent.[16]

History

Adopting a holistic approach to the examination, a thorough history should be obtained from the maternal and neonatal health records, and discussion with parents. Factors within *Table 1* should be considered.

***Table 1* Aetiological factors in congenital heart disease[1,17]**

Factor	Implication	Examples of reluctant heart conditions
Chromosomal	Trisomy 21	Ventricular septal defects, atrioventricular septal defects
	Turner's syndrome	Coarctation of the aorta, aortic/mitral valve stenosis
Associations with other defects	VACTERL association Pierre Robin syndrome	Septal defect
	Charge syndrome, cleft lip and palate	
Familial	Sibling: 2–5% risk of CHD Parent: 5–10% risk of CHD	
Infection	Rubella	Coarctation of the aorta, ventricular septal defects, patent ductus arteriosus
Drugs	Amphetamines, lithium, anticonvulsants	Ventricular septal defects
Teratogens	Alcohol	Septal defects
Maternal conditions	Diabetes mellitus	Ventricular septal defects, transposition of the great arteries
	Systemic lupus erythematosus (SLE)	Congenital heart block
	Phenylketonuria (PKU), obesity	Atrial septal defects, Tetralogy of Fallot, aortic arch defects

A detailed history of the baby's feeding pattern and behaviour should be taken from the parents. The midwife should also observe for the following signs of CHD (see *Box 2*).

***Box 2* Signs and symptoms of potential critical or major congenital cardiac abnormalities[3]**

- Tachypnoea at rest
- Episodes of apnoea lasting longer than 20 seconds or associated with colour change
- Intercostal, subcostal, sternal or suprasternal recession, nasal flaring
- Central cyanosis
- Visible pulsations over the precordium, heaves, thrills
- Absent or weak femoral pulses
- Presence of cardiac murmurs or extra heart sounds
- Grunting
- Poor feeding
- Poor tone

Observation

The midwife should observe whether the baby appears and behaves as expected for its gestation. Good lighting should be used to accurately assess skin colour. Colour is best observed by looking at the lips and mucous membranes, especially in babies with darker skin tones. A healthy baby should be centrally perfused, with no evidence of central cyanosis. Assessment of perfusion is assessed by measuring the capillary refill time, which should be less than three seconds.[11] Although acrocyanosis is considered normal within the first 24–28 hours,[1] central cyanosis can be difficult to detect, so the more objective test of pre-ductal and post-ductal oxygen saturations has been adopted by some NHS hospital Trusts.[18,19] However pulse oximetry is not part of the national NIPE screening programme.[20] The size and shape of the chest, symmetry of chest movement, and use of diaphragm and abdominal muscles should be noted.[3]

Palpation

Peripheral pulses

Femoral and brachial pulses are palpated for rate (110–160 bpm), rhythm and volume as an indicator of cardiac output. Upper and lower extremity pulses should be palpated simultaneously and compared. Weak or absent femoral pulses occur with low cardiac output: for example, coarctation of the aorta; whereas bounding pulses occur with a patent ductus arteriosus.[1]

Precordium

Observation and palpation of the chest wall for vibratory sensations will detect heaves and thrills. The position of the cardiac apex determines if dextrocardia is present, whereby the apex is situated on the right side of the body.

Liver

The liver is engorged in the presence of CHD, when central venous pressure increases. A liver edge would be palpable well below the right costal margin in the case of congestive congenital heart defects.[13]

Auscultation

Auscultation is best accomplished during the quiet, alert or sleep state of the baby.[21] The heart sounds are described as 'lub-dub', the first being documented as S1, the second as S2. The 'lub' is produced by the closure of the mitral and tricuspid valves. The 'dub' is the second heart sound and results from the closure of the aortic and pulmonary valves.[11] It is recommended that practitioners should listen for a full minute at each valve (see *Table 2*) to ensure that two heart sounds are heard, and to rule out any additional sounds.[3]

***Figure 1* Main auscultatory areas of the heart for examination of the newborn**

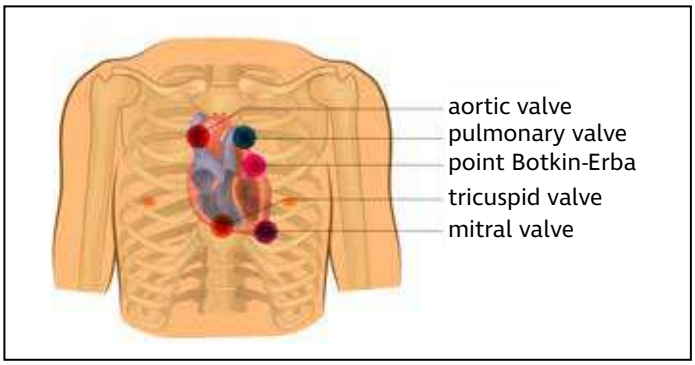

Note: Botkin-Erba point not normally used by midwives as part of the newborn examination.

Table 2 describes the anatomical regions where the stethoscope is placed.

***Table 2* Key auscultatory areas for examination**

Auscultatory area	Stethoscope placement
Pulmonary	Second intercostal space on the left upper sternal border
Aortic	Second intercostal space on the right upper sternal border
Tricuspid	Fourth intercostal space on the lower left sternal border
Mitral	Cardiac apex
Mid-scapulae	Between the scapulae to assess for coarctation of the aorta

MURMURS

Murmurs are the sound produced by the turbulent blood flow through the chambers and large blood vessels of the heart, during the cardiac cycle of contraction and relaxation. Murmurs vary, but all murmurs should be considered as an abnormal finding and referred in accordance with professional responsibilities.[3,16] Significant murmurs are usually loud, heard over a wide area and associated with other findings, whereas benign murmurs are typically short, soft, systolic, and located within the left sternal border, with no other abnormalities.[3]

Cardiac auscultation requires detailed knowledge, practice and experience to ensure competence at distinguishing normal from abnormal; the priority being to master the recognition of normal heart sounds.[22]

REFERRAL

Table 3 illustrates referral pathways for CHD.

***Table 3* Referral pathways for CHD[3]**

Screening outcome	Action to be taken
Screen negative	Repeat examination at 6–8 weeks by a trained healthcare professional. Raise professional and parental awareness of signs of CHD to observe for.
Screen positive	Babies with screen positive cardiac findings following the NIPE newborn screening examination should be seen by a senior paediatrician with expertise in cardiology before discharge home. There are no NIPE cardiac standards. Babies with screen positive findings on examination should follow locally agreed referral processes. The urgency of referral is dependent on the clinical condition of the baby. Local NHS hospital Trusts may require practitioners to measure or repeat pulse oximetry whilst awaiting medical review following a positive screen. Consider the need for a full set of baseline observations to allow for further insight into the overall clinical condition, and/or potential resuscitation.



MESSAGES FOR MIDWIVES

The role of the midwife is to detect deviations from the normal, rather than to diagnose specific congenital heart defects. The parents and baby should remain at the centre of midwifery care. The examination of the cardiovascular system should not be undertaken in isolation; it is part of the wider holistic examination of the newborn infant. **TPM**



FIVE PRACTICE PARTNER POINTS

1. Develop your knowledge by completing the 'Screening examination of the cardiovascular' Unit 3 of the NHS Newborn And Infant Physical Examination e-learning programme.
2. Does your local hospital Trust offer pulse oximetry tests routinely for all babies? Examine the conflicting evidence for this.
3. Develop your clinical experience by following a newborn with a positive screening outcome through the referral process – can you observe the subsequent follow-up care?
4. Consider your experience in identifying cyanosis in babies of different heritage. How can you improve this moving forward?
5. Reflect on your experience in identifying murmurs during cardiac auscultation to date. Have you been able to successfully hear a murmur?

REFERENCES

1. Tappero EP, Honeyfield ME. Physical Assessment of the Newborn: A Comprehensive Approach to the Art of Physical Examination. 6th ed. NewYork, NY: Springer Publishing Company. 2019.

2. Glester T. Congenital cardiac anomalies in the newborn: causes, effects and treatment. In: Davies L, McDonald S, eds. Examination of the Newborn and Neonatal Health: A multidimensional Approach. Edinburgh: Churchill Livingstone. 2008.

3. Newborn and infant physical examination (NIPE) screening programme handbook. Public Health England. https://www.gov.uk/government/publications/newborn-and-infant-physical-examination-programme-handbook/newborn-and-infant-physical-examination-screening-programme-handbook#screening-examination-of-the-heart. Updated April 28, 2021. Accessed June 15, 2021.

4. Richmond S, Wren C. Early diagnosis of congenital heart disease. Semin Neonatol. 2001;6(1):27-35. doi:10.1053/siny.2000.0028.

5. Lardhi AA. Prevalence and clinical significance of heart murmurs detected in routine neonatal examination. J Saudi Heart Assoc. 2010;22(1):25-27. doi:10.1016/j.jsha.2010.03.005.

6. Mirzarahimi M, Saadati H, Doustkami H, Alipoor R, Isazadehfar K, Enteshari A. Heart murmur in neonates: how often is it caused by congenital heart disease?. Iran J Pediatr. 2011;21(1):103-106.

7. Gladman G. Management of asymptomatic heart murmurs. Paediatr Child Health. 2013:;23(2):64-68. doi:10.1016/j.paed.2012.08.004.

8. Green K, Oddie S. The value of the postnatal examination in improving child health. Arch Dis Child Fetal Neonatal Ed. 2008;93(5):F389-F393. doi:10.1136/adc.2007.122465.

9. UK National Screening Committee Statement on newborn examination and early discharge. London: NSC. 2012.

10. Van Woudenberg CD, Wills CA, Rubarth LB. Newborn transition to extrauterine life. Neonatal Netw. 2012;31(5):317-322. doi:10.1891/0730-0832.31.5.317.

11. Bedford C. Cardiovascular and respiratory assessment of the baby. In: Lomax A, ed. Examination of the newborn: An evidence based guide. 3rd ed. Chichester: Wiley-Blackwell. 2021.

12. Arlettaz R, Archer N, Wilkinson AR. Natural history of innocent heart murmurs in newborn babies: controlled echocardiographic study. Arch Dis Child Fetal Neonatal Ed. 1998;78(3):F166-F170. doi:10.1136/fn.78.3.f166.

13. Hoffman JI, Kaplan S. The incidence of congenital heart disease. J Am Coll Cardiol. 2002;39(12):1890-1900. doi:10.1016/s0735-1097(02)01886-7.

14. Campbell D, Dolby L. Physical examination of the newborn at a glance. Chichester: Wiley-Blackwell. 2018.

15. Murphy PJ. The fetal circulation. Contin Educ Anaesth Crit CarePain. 2005;5(4): 107-112.

16. Nursing and Midwifery Council. The Code: Professional standards of practice and behaviour for nurses, midwives and nursing associates. https://www.nmc.org.uk/standards/code. Updated October 10, 2018. Accessed June 15, 2021.

17. Sinha S, Miall L, Jardine L. Essential neonatal medicine. 5th ed. Chichester: Wiley-Blackwell. 2012.

18. Ewer AK, Furmston AT, Middleton LJ, et al. Pulse oximetry as a screening test for congenital heart defects in newborn infants: a test accuracy study with evaluation of acceptability and cost-effectiveness. Health Technol Assess. 2012;16(2):v-184. doi:10.3310/hta16020.

19. Plana MN, Zamora J, Suresh G, Fernandez-Pineda L, Thangaratinam S, Ewer AK. Pulse oximetry screening for critical congenital heart defects. Cochrane Database Syst Rev. 2018;3(3):CD011912. doi:10.1002/14651858.CD011912.pub2.

20. Evans C. Newborn pulse oximetry screening pilot update. Public Health England. https://phescreening.blog.gov.uk/2017/01/10/newborn-pulse-oximetry-screening-pilot-update/. Published January 10, 2017. Accessed June 15, 2021.

21. Brazelton TB, Nugent JK. The Neonatal Behavioral Assessment Scale. 4th ed. London: MacKeith Press/Blackwell. 2011.

22. McDonald S. The practical examination of the newborn. In: Davies L, McDonald S, eds. Examination of the Newborn and Neonatal Health: A multidimensional Approach. Edinburgh: Churchill Livingstone. 2008.

Chapter summary

Key learning points

EXAMINATION OF THE NEWBORN: THE KEY SKILLS
3. THE HIPS



> AUTHORS



Natasha Carr (she/her)
Senior Lecturer in Midwifery and Course Lead in Midwifery, Birmingham City University

Ruby Handley-Stone
Midwifery Lecturer, Birmingham City University

Paola Armato-Harris
Midwifery Lecturer, Birmingham City University

Samantha Meegan
Senior Midwifery Lecturer, Birmingham City University

Samuel Todd
Midwifery Lecturer, Birmingham City University
Twitter @BCUMidwives

SUMMARY

Midwives are increasingly performing the newborn and infant physical examination (NIPE), particularly now the new Nursing and Midwifery Council (NMC) education proficiencies are inclusive of the systematic examination of the newborn infant.[1] This article, the third in the series, considers the importance of the examination of the hips in this screening process.

The significance of history taking, knowledge of risk factors and the hip examination are explored. The necessity for early detection and treatment of hip abnormalities, along with referral pathways that Public Health England requires, are highlighted. The impact of late detection of developmental dysplasia of the hip on the lives of families and children are also considered.

INTRODUCTION

Developmental dysplasia of the hip (DDH) describes a condition where the femoral head has an abnormal relationship with the acetabulum of the pelvis. Traditionally the term 'congenital dislocation of the hip' was used to describe this disorder[2]; however some of the features of dysplasia may not be present at birth and the term 'developmental' more accurately reflects all the stages of skeletal development.[3] DDH is known to develop either in utero, after birth or even during childhood, at any time during the development of the skeleton.[4] The Public Health England (PHE) screening programme[5] aims for early detection of a dislocated or dislocatable hip and to minimise the risk of long-term complications by timely referral for an ultrasound scan, expert opinion and early intervention.

HIP DEVELOPMENT

By the 11th week of fetal life, the hip is fully formed, although it is a cartilaginous joint and vulnerable to external forces in utero. The head of the femur and acetabulum are integrally related. Normally the head of the femur (ball) sits snugly in a rounded, deep acetabulum (socket). When positioned correctly, the femoral head will help shape the cavity of the acetabulum and normal growth relies upon this relationship. When positioning of the ball and socket is restricted, a shallow socket may result, for example in oligohydramnios. It is the free movement of the lower limbs and hip joints that facilitates correct development. From 36 weeks gestation onwards, the risk of DDH is higher, as fetal movement can be compromised by breech presentation or a macrosomic baby.[6,7]

The baby continues to be at risk of DDH following birth. The baby's legs move from 'flexion – adduction' to more 'extension – adduction', putting them at further risk of DDH.[7] This can be exacerbated by the practice of swaddling. Swaddling may press the legs into a position of extension, forcing the hips to straighten and shift forward, therefore raising the potential for misalignment and dislocation.[8] The key factors for the natural development of the hips is to allow plenty of hip movement, hip flexion and adduction.[9]

***Table 1* Abnormalities that may present in the hip. Hip dysplasia refers to misalignment between the femoral head and the acetabulum, resulting in pathogenic instability[3]**

Subluxated	Partial dislocation of a joint so that the femoral head and acetabulum are misaligned but still in contact.
Dislocated	There is incomplete contact between the surfaces of the femoral head and the acetabulum. Dislocation by displacement of the head of the femur from the acetabulum can occur anteriorly or posteriorly.
Dislocatable	This refers to a joint that has too much movement or laxity. The hip has the ability to subluxate or dislocate with passive manipulation.
Normal	The femoral head fits into the acetabulum and creates a snug hip joint. It is held tightly in place by ligaments and joint capsule, creating a ball and socket joint.[6]

Table 1 illustrates a range of abnormalities that can occur in the hip joint. If left undetected and uncorrected, the long-term negative sequelae for children and adults can be seriously debilitating.[5] Delay in diagnosis means that children will endure more complex invasive treatments with higher failure rates. Early diagnosis with prompt appropriate treatment is essential.

When normal hip development occurs, the fetus, baby and child should thrive; however, where DDH occurs at any stage, the consequences for all those involved can be devastating, particularly for the child: one parent, Oonagh Keith, explains why late detection can have a devastating effect.

'*When my daughter Siomha started to walk at 13 months, she would only lead with her right leg and appeared to limp. She was diagnosed with severe developmental dysplasia of the hip, which is a complete dislocation and no socket had formed. It later transpired that she had not been examined at birth. I was not aware of what the hip check was for, how it was carried out and how important it was. She was operated on at 21 months, by which time her left leg was significantly shorter and you could feel the head of the femur when you carried her. The surgeon used a part of her pelvis to create a basic socket (pelvic osteotomy) and her tendon was severed in her groin as they had become too tight and would have caused further dislocation. She was then encased in a hip spica cast that went from her chest to her ankle so that she was totally immobilised. She spent six weeks in the cast, which was then removed under general anaesthetic. Shortly after the cast removal, during a routine visit to the hospital, she contracted norovirus and was so unwell that she vomited blood after ripping the lining of her stomach. Her general health was on a spiral downwards and there was nothing I could do. She suffered significant muscle wastage and required a number of years of intense physiotherapy to strengthen her left side. Siomha is now 14 years old and beginning her GCSEs. She is a delightful young lady, bright, emotionally intelligent and extremely vocal against any inequality. She is very aware of the long-term implications of DDH and she continues to be monitored by her surgeon as further surgery may be required as well as early hip replacement.*'

> *"Developmental dysplasia of the hip (DDH) describes a condition where the femoral head has an abnormal relationship with the acetabulum of the pelvis.[14]"*

INCIDENCE

The incidence of DDH remains unclear due to some cases being diagnosed at birth and some later on. It may affect one or both hips and is more common in the left hip, in girls and first-born children. Only one to two in 1,000 babies have DDH that will need surgical treatment, while three to five per 1,000 live births may require a Pavlik Harness.[5]

RISK FACTORS

The aetiology of DDH is multifactorial and complex; consequently the midwife must be alert to a combination of factors in the assessment of the newborn. PHE recognises three national hip risk factors that increase risk for DDH: namely a first-degree family history of hip problems in early life; breech presentation at or after 36 completed weeks of pregnancy, irrespective of mode of presentation at birth (including external cephalic version babies); and breech birth from 28 weeks gestation. In addition, in a multiple pregnancy where any of these risk factors are present, then all babies should receive a hip ultrasound. These should necessitate a referral,[5] although many other factors have been identified as being associated with DDH. All factors are highlighted in *Table 2*.



Table 2 **National and other risk factors for DDH in the newborn, as identified by the NHS newborn and infant physical examination (NIPE) programme**

Risk factors (national)[3]	Explanation of risk factors
Family history[5]	Risk of DDH rises dramatically where a parent and sibling have DDH to a 1 in 3 risk of a future child having DDH[6]
Breech[5]	Potential lack of fetal movement at the critical 36-week point. The position of the fetus in utero puts pressure on hip joints and stretches ligaments and the hip capsule, thus allowing for potential dislocation[6,7]
Reduced liquor	Restricted movement in utero
Fixed foot deformities, such as talipes equinovarus	Restricted movement in utero
Stiffness in the neck, such as torticollis	Restricted movement in utero and malpositioning
Female infants	Hormonal influences (relaxin) affecting female babies[10,11]
High birthweight	Restricted movement in utero
Syndromic, such as Trisomy 21	Hypotonic baby, lax hip joints
Positional foot deformities, such as metatarsus adductus, calcaneovalgus	Intrauterine crowding and restricted movement
Extrauterine factors, such as swaddling	Restricted movement in the postnatal period, more prevalent in some ethnic groups or cultures or practices[9]
Intrauterine factors, such as oligohydramnios, first-born infants	Restricted movement from lack of liquor and taut abdominal muscles

EXAMINATION

The examination of the hips is part of the entire assessment of the musculoskeletal system. Prior to any physical examination, the midwife should enquire of any parental concerns.[5] Consent must also be sought as per NMC principles.[12]

History

A full detailed history should elicit the conditions and risk factors associated with DDH (See *Table 2*). PHE[5] stresses the importance of ascertaining a first-degree family history of hip problems in early life. Midwives should ask the question: 'Is there anyone in the baby's close family (mother, father or sibling) who has had a hip problem, starting in infancy or early childhood, that needed treatment with a splint harness or an operation?' Don't forget to review all antenatal, labour and postnatal records.

Observation

The baby should be calm and relaxed, placed on a flat firm surface with the nappy removed.[13,14] The midwife should observe the baby for equal leg length and range of movement of the lower limbs. Asymmetry of the gluteal skin folds is no longer used as a screening tool.

With the baby in a supine position, the Allis sign can be observed. While keeping the feet flat and the femurs aligned, both knees should be flexed. With the big toes in the same horizontal plane, the midwife can observe the height of the knees. If one knee is higher than the other this is a positive sign that the hip could be dislocated.[14]

Palpation

The two tests for assessing hip stability are the Ortolani and Barlow manoeuvres. Although clinicians in practice may still be examining both hips simultaneously, the most reliable method for detecting hip instability is to examine one hip at a time.[5,15] Godley[15] insists that stabilisation of the pelvis is crucial to the successful execution of the manoeuvres and this is the current recommended practice.[5]

The Ortolani manoeuvre

The Ortolani manoeuvre tests whether an already dislocated head of femur can be relocated into the acetabulum. The baby should be relaxed in a supine position. The hip should be flexed to 90 degrees. The midwife should firmly support the pubic symphysis and sacrum with one hand to stabilise the pelvis.

With the other hand, the midwife should locate the greater trochanter with their index and middle finger and the thumb being placed on the inner thigh. The femur is elevated and adducted gently, resulting in a relocation of the dislocated hip. A positive Ortolani sign is described as a palpable and sometimes audible clunk as it reduces back into the acetabulum.[16]

The Barlow manoeuvre

The Barlow manoeuvre will dislocate a dislocatable hip.[16] Again, this manoeuvre requires a steady stabilisation of the pelvis with one hand and is performed with the hips flexed to 90 degrees. This time the hip should be slightly adducted. The midwife should apply downwards, backwards pressure to try to gently push the femoral head out of the acetabulum, over the posterior rim.

It should be noted that these tests are not robust indicators of DDH. The Barlow can be criticised for its poor predictive value. The Ortolani is a more sensitive test but still misses a significant number of DDH cases.[16]

Clicks and snaps are sometimes heard or felt during the manoeuvres but these are not normally associated with hip pathology. These noises are usually a result of the movement of tendons, ligaments or fluid in the hip joint.[14] Isolated clicks are not considered clinically significant by the NHS NIPE screening programme and without any other relevant clinical findings should therefore not be classified as screen positive and do not require referral for ultrasound.[5]

Any abnormalities detected during the examination should be referred. PHE[5] identifies two risk factors for referral (breech and family history). NIPE practitioners should consult their local guidelines for any additional criteria such as metatarsus adductus or calcaneovalgus that may be included in the referral pathway.

Where the findings of the examination of the hips are normal, Paton and Davis,[16] and PHE[5] remind us that some instabilities may not have been identified during the examination. In view of this the midwife should inform parents of the signs of DDH as part of their wider public health role[5] (*Box 1*).

Box 1 **Signs of DDH in the baby and infant[5]**

- One leg cannot be moved out sideways as far as the other when changing the baby's nappy
- One leg seems to be longer than the other
- One leg drags when the baby starts crawling
- The child walks with a limp or has a 'waddling' gait when they start walking.



"When normal hip development occurs, the fetus, baby and child should thrive; however, where DDH occurs at any stage, the consequences for all those involved can be devastating, particularly for the child."

REFERRAL AND SUPPORT

The summary in *Table 3* illustrates the referral pathway for DDH that NIPE practitioners should follow. The complete process referral map for DDH screening is available from PHE.[5] For those parents with a baby diagnosed with DDH, further support will be required once a referral has been made.

***Table 3* Referral pathways for DDH for midwives[5]**

Screening outcome	Action to be taken
Screen negative on clinical examination and no national hip risk factors	Repeat NIPE infant screening at 6–8 weeks. Continue with routine care and advice.
Screen positive on clinical examination i.e. • Difference in leg length • Knees at different levels when hips and knees are bilaterally flexed • Restricted unilateral limitation of hip abduction (with a difference of 20 degrees or more between hips) • Gross bilateral limitation of hip abduction (loss of 30 degrees abduction or more) • Palpable 'clunk' when undertaking the Ortolani or Barlow manoeuvre.	Attend for ultrasound scan of the hips between: • 4–6 weeks of age for babies born ≥34 weeks and zero days (34+0) gestation • 38+0–40+0 weeks corrected age for babies born <34+0 weeks gestation. Babies who attend for ultrasound scan of the hips after screen-positive referral should have an outcome decision (discharged if normality confirmed and seen by orthopaedic specialist) if abnormality confirmed made by: • 6 weeks of age for babies born ≥34 weeks and 0 days (34+0) gestation • 40+0 weeks corrected age for babies born <34+0 gestation. Ensure that babies who require treatment enter the treatment pathway by 6 weeks of age.
National risk factors alone	Same action as for screen positive above.

RECORD KEEPING

Results should be recorded on the electronic SMaRT4NIPE (S4N) NIPE screening system ideally or an alternative maternity IT system. Orthopaedic and ultrasound services can access this too, supporting timely input and follow up of referral outcomes. The personal child health record or local clinical records should also be updated.

The NIPE lead is accountable and responsible for timely collation of accurate and reliable data. Using the NIPE screening management and reporting tool S4N IT system, they will manage the local screening process. This data is extracted from S4N by the national programme and utilised.

***Table 4* Terminology of the musculoskeletal system to assist with hip examination**

Abduction	Moving a limb away from the midline of the body
Adduction	Moving a limb towards or past the midline of the body
Extension	Straightening a limb at a joint
Flexion	Bending a limb at a joint
Supine	Lying horizontally with the face and torso (ventral side) facing upwards and the back downwards (dorsal side)
Prone	Lying horizontally with the dorsal side facing up and ventral side downwards
Posterior	Located behind or to the rear of a structure
Anterior	Near or at the front

MESSAGES FOR NIPE PRACTITIONERS

- Each hip should be assessed separately while the other hand stabilises the pelvis. Simultaneous assessment of both hips is not recommended.
- As part of their public health role, midwives need to empower parents with information and signs of DDH, as it may not always be detected during the first systematic examination.
- Prompt referral along the correct[5] pathway will ensure early treatment of DDH to optimise the long-term health of the baby and developing child.
- Midwives must ensure families are aware of the services available when DDH is suspected or diagnosed, so that support is continued beyond midwifery care.
- Be aware of parenting trends that can impact hip development.[17]

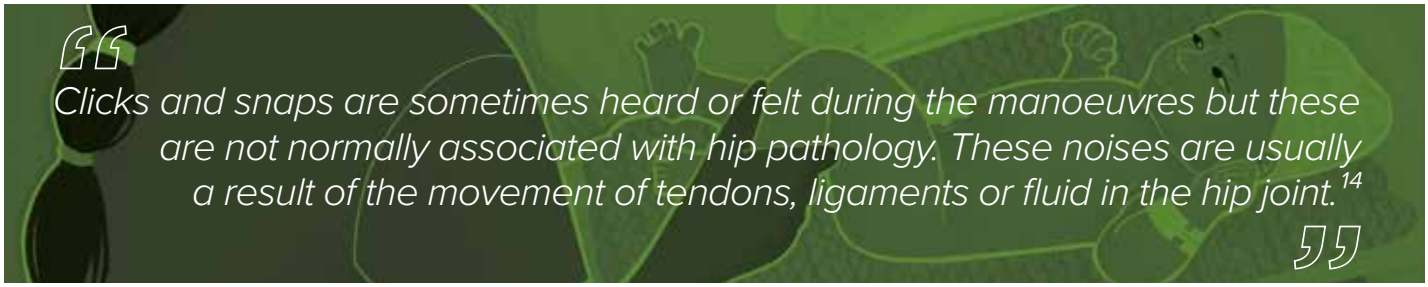

QUESTIONS

- Did you know that all student midwives are undertaking the systematic examination of the newborn (NIPE) as part of their undergraduate midwifery programmes? Get in touch with your local university and see how you can get involved.
- Have you read the latest PHE guidance on the NIPE?[5] Download the programme handbook and check you are practising in the latest evidence-based way.
- Reflect on your recent NIPE examinations as part of your NMC revalidation requirements.
- Access your local Trust's examination of the newborn policy – does it need updating in line with the new evidence base and recommendations?
- What is the value of having a national S4N NIPE system?
- What do you know about healthy swaddling, babywearing and transporting?

FURTHER RESOURCES

The online training resources for the NIPE examination showing film and animation of the Ortolani and Barlow manoeuvres are available free of charge on the e-Learning for Healthcare website.[18]

The Royal College of Midwives' website offers a free online learning module on i-learn, which has a video animation of the manoeuvres available.[19]



REFERENCES

1. Nursing and Midwifery Council. Standards of proficiency for midwives. https://www.nmc.org.uk/globalassets/sitedocuments/standards/standards-of-proficiency-for-midwives.pdf. Published November 18, 2019. Accessed March 4, 2022.

2. Dupuytren G. Original or congenital displacement of the heads OF THIGH-bones. Clin Orthop Relat Res. 1964;33:3-8.

3. Wilkin GP, Ibrahim MM, Smit KM, Beaulé PE. A Contemporary Definition of Hip Dysplasia and Structural Instability: Toward a Comprehensive Classification for Acetabular Dysplasia. J Arthroplasty. 2017;32(9S):S20-S27. doi:10.1016/j.arth.2017.02.067.

4. Klisic PJ. Congenital dislocation of the hip--a misleading term: brief report. J Bone Joint Surg Br. 1989;71(1):136. doi:10.1302/0301-620X.71B1.2914985.

5. Newborn and infant physical examination (NIPE) screening programme handbook. Public Health England. https://www.gov.uk/government/publications/newborn-and-infant-physical-examination-programme-handbook/newborn-and-infant-physical-examination-screening-programme-handbook. Updated April 28, 2021. Accessed March 2, 2022.

6. What is hip dysplasia? Brochure. International Hip Dysplasia Institute (IHDI). Orlando: IHDI; 2021.

7. Hurley A. DDH: causes and examination. Community Pract. 2009;82(9):36-37.

8. Torjesen I. Swaddling increases babies' risk of hip abnormalities. BMJ. 2013;347: f6499. doi:10.1136/bmj.f6499.

9. Clarke NM. Swaddling and hip dysplasia: an orthopaedic perspective. Arch Dis Child. 2014;99(1):5-6. doi:10.1136/archdischild-2013-304143.

10. Roposch A, Protopapa E, Cortina-Borja M. Weighted diagnostic criteria for developmental dysplasia of the hip. J Pediatr. 2014;165(6):1236-1240.e1. doi:10.1016/j.jpeds.2014.08.023.

11. Mace J, Paton RW. Neonatal clinical screening of the hip in the diagnosis of developmental dysplasia of the hip: a 15-year prospective longitudinal observational study. Bone Joint J. 2015;97-B(2):265-269. doi:10.1302/0301-620X.97B2.34858.

12. Nursing and Midwifery Council. The Code: Professional standards of practice and behaviour for nurses, midwives and nursing associates. http://www.nmc.org.uk/globalassets/sitedocuments/nmc-publications/revised-new-nmc-code.pdf. Updated October 10, 2018. Accessed March 2, 2022.

13. Campbell D, Dolby L. Physical examination of the newborn at a glance. Oxford: Wiley Blackwell; 2018.

14. Tappero, EP, Honeyfield ME. Physical assessment of the newborn: A comprehensive approach to the art of physical examination. 4th ed. California: NICU INK Book Publishers; 2019.

15. Godley DR. Assessment, diagnosis, and treatment of developmental dysplasia of the hip. JAAPA. 2013;26(3):54-58. doi:10.1097/01720610-201303000-00011.

16. Paton RW, Davis N. Development dysplasia of the hip and abnormalities of the foot. In: Lomax A, ed. Examination of the newborn: An evidence based guide. 3rd ed. Chichester: Wiley-Blackwell. 2021.

17. Bates C. Trendy mothers who swaddle their babies are causing resurgence in hip problem that died out 25 years ago. MailOnline. https://www.dailymail.co.uk/health/article-2113905/Mothers-swaddle-babies-causing-hip-problems-died-25-years-ago.html. Updated March 12, 2012. Accessed March 4, 2022.

18. Providing elearning to educate and train the health and care workforce. e-learning for healthcare. https://portal.e-lfh.org.uk. [Date unknown]. Accessed March 8, 2022.

19. Welcome to i-learn. Royal College of Midwives i-learn. https://www.ilearn.rcm.org.uk. [Date unknown]. Accessed March 8, 2022.

Chapter summary

Key learning points

EXAMINATION OF THE NEWBORN: THE KEY SKILLS

4. THE TESTES



> AUTHORS



Paola Armato-Harris
Midwifery Lecturer, Birmingham City University

Natasha Carr
Senior Lecturer in Midwifery and Course Lead in Midwifery, Birmingham City University

Ruby Handley-Stone
Midwifery Lecturer, Birmingham City University

Samantha Meegan
Senior Midwifery Lecturer, Birmingham City University

Samuel Todd
Midwifery Lecturer, Birmingham City University
Twitter @BCUMidwives

SUMMARY

As the role of the midwife continually evolves and expands, midwives are increasingly performing the examination of the newborn. With a focus and national drive on providing continuity of care in conducting the newborn and infant physical examination (NIPE), many midwives view this assessment as a natural extension to their role[1] and continually strive to provide high-quality, individualised care.

In the penultimate edition of this five-part series, we consider the importance of the examination of the testes in the screening process. The significance of relevant history taking, knowledge of risk factors and a detailed examination of the testes will be explored, along with referral pathways in line with the requirements of the national screening programme. The impact of late detection and poor referral of undescended testes on the lives of children and adults will also be considered.

INTRODUCTION

A comprehensive physical assessment of the newborn includes the evaluation of the genitourinary system,[2] and this article particularly focuses on the examination of male genitalia. Any issues with female genitalia are equally important and must be clearly documented and referred if necessary, and there should be particular urgency if safeguarding concerns are highlighted. The genital examination of the newborn, although pertinent in the detection of life-threatening conditions, and despite documented progress in newborn examination as a whole, has not been well researched and remains problematic.[1] Even with all efforts to ensure a thorough and detailed examination, clinicians risk the omission of pertinent details as a cursory examination, heavily reliant on observational elements, takes precedence.[1] As this examination increasingly falls on the expertise of the midwife, the importance of identification of abnormalities of the genitalia must never be underestimated. With a comprehensive understanding of the physical aspects of examination, practice that draws on the most current evidence and a structured approach, midwives can positively influence the long-term wellbeing of the neonate and significantly contribute to the prevention of future morbidity and mortality.

> *"As experts in normality, when performing the examination of the genitalia, it is vital that midwives have a sound understanding of the embryological process of sex determination, making it easier to then highlight when deviations occur."*



TESTES DEVELOPMENT

As experts in normality, when performing the examination of the genitalia, it is vital that midwives have a sound understanding of the embryological process of sex determination, making it easier to then highlight when deviations occur. The fetus is without gender until approximately the seventh week of gestation.[3] Chromosomal influence will determine the differentiation of the testes with the XY sex chromosome combination. The presence of sex-determining proteins and factors during the further embryonic period initiates the process of male sex determination and the primitive gonads to develop into testes. Normal development of the male fetus sees the testes initially forming in the abdomen. At approximately 28 weeks gestation, the testes should begin their descent into the scrotum. The descent commences through the internal inguinal ring, into the inguinal canal, proceeding to the external inguinal ring and then into the scrotum.[1] This descent into the scrotum is essential as spermatogenesis cannot occur at the warmer intra-abdominal temperature.[4] This whole process should be completed by birth; however, if a baby is born prematurely, this process may be interrupted and hence becomes a risk factor for undescended testes. Risk factors should alert midwives to those babies at greater risk of abnormalities (*See Boxes 1* and *2*).

RISK FACTORS

Box 1 **The risk factors for undescended testes to be considered by the midwife[5]**

- Low birthweight
- Small for gestational age
- Preterm birth
- First-degree history of cryptorchidism

Box 2 **Key factors alerting to potential genitourinary abnormality[2]**

- Polyhydramnios
- Oligohydramnios
- Family history – genetic predisposition
- Flattened face
- Malformed ear
- Contraction deformities of limbs
- Oliguria/anuria

CRYPTORCHIDISM

Cryptorchidism (undescended testes) is the failure of one testis or both testes to permanently descend and is one of the most common congenital abnormalities observed in males.[6] Undescended testes, or cryptorchidism, occurs when there is a disruption in the embryological processes that regulate descent and has serious consequences for the future health of the male. A history of cryptorchidism increases the risk of infertility. Evidence suggests that individuals with bilateral undescended testes are more affected than those with unilateral,[7] however,

prompt recognition and early treatment are believed to significantly improve fertility. Cryptorchidism is also associated with a significant increase in the risk of testicular cancer. It is thought that 5% of testicular cancers are associated with cryptorchidism.[1]

INCIDENCE

Cryptorchidism is one of the most common congenital malformations in the male,[8] with a prevalence of approximately 2–6% of male babies born at term. One in 100 of these babies will have testes that stay undescended unless treated.[5]

EXAMINATION

History

Prior to any physical examination, the midwife should ascertain the birthing person's medical, family, antenatal, intrapartum and neonatal history, and also enquire of any parental concerns.[5] In particular, any history of hereditary cryptorchidism should be identified. Consideration should be made by the midwife to ensure conversations take place where privacy and dignity are upheld in light of the sensitivity of the information that may be exchanged.[9]

Observation

Prior to initial observations, the midwife must aim to examine the baby in full view of the parent/parents if circumstances allow. The examination should follow a systematic process in order to avoid vital omissions.[10] Observation is the most important, yet most difficult, part of the physical assessment technique to master.[10] To ensure a thorough and effective examination, the external male genitalia and urogenital area should be inspected with the infant in the supine position. Gestational age impacts the appearance of the external genitalia of the male baby, so it is essential that the midwife assesses the gestational age of the infant accurately, as this will better inform the examination.[2] Normal features of the male infant's anatomy to observe should include the penis, meatus, scrotum, raphe, anus and testes.

Palpation

Palpation of the testes is ideal in the neonate as not only is the neonate relatively restricted in its mobility, the cremaster reflex is immature.[1] This is the reflex that causes retraction of the testicle when the skin over the ipsilateral Scarpa's triangle or the inner side of the thigh is stroked, and errors should be minimised due to this phenomenon. The scrotal sac and the inguinal canal should be palpated systematically on the left and right to detect any masses. It is advisable to palpate from the top of the groin down towards the scrotum, bilaterally using two fingers, then the thumb and forefinger are used to palpate for the presence of each testis in the scrotal sac.[1] A firm, smooth and equal size testis should be located in each scrotal sac, which should be mobile, and measure around 1–1.5 cm.[1] Once located, a testis should be isolated in order to assist the confirmation of two separate testes. Palpation of the inguinal canal should be repeated if the testes are not located in the scrotal sac.[5] No masses should be found in the inguinal canals. A mass may indicate an inguinal hernia (or undescended testis) which results from the persistence of the proximal part of the processus vaginalis through which loops of intestine herniate.[2] As the term 'undescended' applies to clinical findings of either 'absence' or 'incorrect position' of the testes, it is important to note that whilst palpating the inguinal canal, the midwife should consider palpating just below the groin, as the testicle may have descended abnormally.[11] Where testes are felt bilaterally but high in the inguinal canal, this should be managed as screen positive.[5]

Figure 1 **Illustration of the external appearance of the male genitalia and internal anatomy. During fetal development, the testes are formed in the abdomen. Around the seventh month of gestation, the testes normally move from the abdomen to the scrotum. Most undescended testes will descend within 12 months of birth.**



Photo: Peter Gardiner/Science photo library

INSPECTION

Penis

The penis should be inspected to ensure it is present, of correct location and is of an appropriate size, considering that the size of the penis at birth varies considerably.[11] Although it is not common practice to measure in the UK, reference ranges of 3–3.5 cm are quoted as being normal.[1,2] Midwives should consider the influence of suprapubic fat in the neonate that can make the penis appear shorter.[1] The withdrawal of the foreskin is not recommended, as normal presentation may see the foreskin adhered to the glans penis.[1]

Urethral meatus

The urethral meatus should be visualised if possible, however is not necessary if normal formation of the prepuce has been identified, with no bending (chordee) evident and the passing of urine confirmed.[1] The parents should be questioned to ensure that the neonate has urinated and that a strong, straight, continuous stream of urine has been seen. The meatus should be centrally positioned on the tip of the penis. Location of the meatus on the dorsal surface of the penis (epispadias), or more commonly on the ventral surface of the penis (hypospadias), is abnormal and requires referral for corrective surgery.

Hypospadias is one of the most common congenital anomalies, thought to be increasing with incidence of one in 250 births.[12] It is caused by a failure of fusion of the urethral folds in the embryological phase and can vary in severity, relating to the point in time when the interruption to development occurred.[13]

In hypospadias, the urethral meatus opens onto the underside of the glans penis, the penile shaft or the perineum. Calonge and Sapino state that hypospadias is often accompanied, or associated with, abnormalities of the foreskin and curvature of the penile shaft.[12] Severe hypospadias and undescended testes require urgent referral to exclude a possible sex developmental problem. Increased incidence of hypospadias is associated with low birthweight and poor intrauterine growth, with maternal risk factors thought to include low body mass index (BMI), family history in first-degree relatives and advanced maternal age.[13] Babies with hypospadias will require surgery between six to twelve months of age and therefore parents should be strongly advised against having their infants circumcised to optimise the success of the repair.

The scrotum

Specific to the scrotum, the midwife should observe the size, shape and colour of the scrotal sacs. With thorough observations, conditions such as a hydrocele, or testicular torsion may be promptly identified. The scrotum may present as relatively smooth or be fully rugated and more deeply pigmented than the surrounding skin if the infant is term.[2] Pigmentation of the scrotum is common, particularly in babies born to parents with darker skin tones, however it may be an early finding in neonatal torsion of the testis or congenital adrenal hyperplasia.[11] Some neonates may have oedema or bruising (ecchymosis) of the scrotum due to birth trauma such as breech birth; careful history taking, documentation and reassuring parents that this is transient are important.

A hydrocele may be apparent on inspection or palpation of the scrotum, where the scrotum may appear enlarged or asymmetrical. A hydrocele is an accumulation of fluid in the scrotum between the visceral and parietal areas of the tunica vaginalis that is usually the result of incomplete closure of the processus vaginalis. A definitive diagnosis is achieved by transillumination of the scrotum and despite occurring in 2–5% of newborn males, most resolve spontaneously within 12 months.[1] The presence of a hydrocele may or may not be associated with inguinal hernia.

REFERRAL

Any suspicion of an abnormality of the newborn male genitalia warrants an immediate referral to the paediatrician. Timeliness of the first appointment for babies with bilateral undescended testes is by 24 hours with a paediatrician. The summary in *Table 1* illustrates the referral pathway that midwives should follow. NIPE recommends prompt referral with all cases of persistent cryptorchidism to a surgeon by 13 months.

***Table 1* Referral pathway for undescended testes[5]**

Findings		Action	
Both testes palpable in scrotum Screen negative		All babies re-examined at 6–8 weeks of age by trained healthcare professional.	
One undescended testis Screen positive findings of unilateral undescended testis	No further action. Raise parental and professional awareness. Repeat examination at 6–8 weeks of age by trained healthcare professional.	If persistent, unilateral undescended testis following NIPE infant screening 6–8-week examination should be reviewed by a GP between 4–5 months of age, then be referred to a surgeon if testis still absent or not descended (to be seen no later than 6 months of age).	Surgery by 2 years old.
Bilateral undescended testes Screen positive findings of bilateral undescended testes	Urgent referral to senior paediatrician within 24 hours of the examination to rule out metabolic and disorders of sex development conditions.	Infants with screen positive findings of bilateral undescended testes following NIPE infant screening 6–8-week examination should be referred and seen by a senior paediatrician within 2 weeks of the examination.	If remain undescended, referred and seen by surgeon by 1 year old. Surgery by 2 years old.

MESSAGES FOR MIDWIVES

The examination of the genitalia is a key skill required as part of the screening of the newborn. Accurate information needs to be given to parents sensitively and in an appropriate examination environment. Parents must be aware of the correct referral and treatment options available to them. Accurate documentation by midwives will assist this process, by ensuring communication of care to the wider multidisciplinary team and next healthcare professional in the referral pathway. The early detection, monitoring and treatment of cryptorchidism are essential to the long-term physical and mental health of the male infant, child and adult. Parents should be advised to contact their midwife, GP or health visitor if concerned about their baby's testes. **TPM**



FIVE PRACTICE PARTNER POINTS

1. Further your knowledge by completing the 'Screening examination of the testes' Unit 5 of the NHS Newborn and Infant Physical Examination e-learning programme.
2. Does the referral pathway for cryptorchidism in your local maternity or perinatal services differ slightly from that of Public Health England? Become familiar with your local protocol to ensure a timely, efficient and robust referral pathway.
3. Develop your clinical experience by following a newborn with a positive bilateral screening outcome through the referral process – consult with a neonatologist and request to observe the subsequent follow-up care.
4. Are you aware of the terms 'retractile' and 'true undescended' testis? Review the evidence and relevant skills applied to these terms in order to develop your knowledge and practice.
5. Reflect on your experience in identifying complex conditions in the examination of the testes and genitalia. Use this reflection to form part of your revalidation and demonstrate your commitment to improved practice in this area.

REFERENCES

1. Gordon M. Examination of the newborn abdomen and genitalia. In: Lomax A, ed. Examination of the Newborn: An Evidence Based Guide. 2nd ed. Chichester: Wiley-Blackwell; 2015.
2. Tappero EP, Honeyfield ME. Physical Assessment of the Newborn: A Comprehensive Approach to the Art of Physical Examination. 6th ed. California: NICU INK Book Publishers; 2019.
3. Webster S, de Wreede R. Embryology at a glance. 2nd ed. Sussex: Wiley Blackwell; 2016.
4. Silber S. Fundamentals of Male Infertility. Germany: Springer International Publishing; 2018.
5. Newborn and infant physical examination (NIPE) screening programme handbook. Public Health England. https://www.gov.uk/government/publications/newborn-and-infant-physical-examination-programme-handbook/newborn-and-infant-physical-examination-screening-programme-handbook. Updated April 28, 2021. Accessed September 22, 2021
6. Gurney JK, McGlynn KA, Stanley J, et al. Risk factors for cryptorchidism. Nat Rev Urol. 2017;14(9):534-548. doi:10.1038/nrurol.2017.90.
7. Chung E, Brock GB. Cryptorchidism and its impact on male fertility: a state of art review of current literature. Can Urol Assoc J. 2011;5(3):210-214. doi:10.5489/cuaj.10106.
8. Grinspon RP, Gottlieb S, Bedecarrás P, Rey RA. Anti-Müllerian Hormone and Testicular Function in Prepubertal Boys With Cryptorchidism. Front Endocrinol. 2018;182(9). doi: 10.3389/fendo.2018.00182. In: Ivell R, Spencer Barthold J (eds). Cryptorchidism: Causes and Consequences. Lausanne: Frontiers Media SA; 2019.
9. Nursing and Midwifery Council (NMC). The Code: Professional standards of practice and behaviour for nurses, midwives and nursing associates. London: NMC; Updated 2018.
10. Campbell D, Dolby L. Physical Examination of the Newborn at a Glance. Hoboken, New Jersey: Wiley Blackwell; 2018.
11. Baston H, Durwood H. Examination of the Newborn: A Practical Guide. 3rd ed. London: Taylor & Francis Group; 2016.
12. Calonge WM, Sapino G. An Overview of Hypospadias Surgery. In: Amr, S, ed. Issues in Flap Surgery. London: IntechOpen; 2018.
13. Hutton KAR. Hypospadias. Paediat Child Health. 2010;20(11):539-540. doi:10.1016/j.paed.2010.06.003.

Chapter summary

Key learning points

CARE CLOSE TO HOME: A SPOTLIGHT ON THE NEWBORN AND INFANT PHYSICAL EXAMINATION



SUMMARY

This article is the final in a five-part series exploring the Newborn and Infant Physical Examination (NIPE). It focuses on the role of the practitioner and how this can contribute to continuity of carer and improving the postnatal experience of women and birthing people. Furthermore, this article will provide suggestions to support undertaking the NIPE in the woman's own home and how maternity services can support early transfer back home following birth in a hospital setting.

> AUTHORS

Samuel Todd
Birth Centre Manager at Birmingham Women's and Children's NHS Foundation Trust; previously Lecturer in Midwifery at Birmingham City University
Twitter @samueltodd16

Dayna Wright
Lead Midwife for Homebirth Team and Continuity of Carer Teams, Birmingham Women's and Children's NHS Foundation Trust and NIPE Practitioner
Twitter @DaynaWright1

Cathy Green
Bank Home Birth Midwife, Birmingham Women's and Children's NHS Foundation Trust and NIPE Practitioner
Twitter @Cathygreen8

Bryony Todd
Clinical Fellowship Midwife, Walsall Healthcare NHS Trust
Twitter @ToddBryony

https://doi.org/10.55975/DZZF4489

INTRODUCTION

It is now recognised that maternity services should deliver care closer to a woman or birthing person's home.[1] Benefits of offering care in this way may include a reduction in unnecessary travel and the associated costs, better utilisation of both the clinician and woman's time and reduced hospital-based appointments. This may contribute to improving the experience of a woman's pregnancy journey. However, the literature only refers to the usage of 'community hubs' as a way for maternity services to achieve this ambition.[1,2]

For midwives working in home-birth teams or continuity of carer teams the woman's own 'home' might be the location for the majority of care during pregnancy, childbirth and postnatal period. In contrast, for women or birthing person receiving care led by community midwives the majority of appointments will be undertaken in health centres, children's centres or community hubs. The NIPE is one aspect of care that is usually undertaken in a hospital setting either before the woman is transferred to community or as an outpatient appointment. This paper will explore the feasibility of undertaking this examination within a woman's home in order to provide care 'closer to home'.

Bryony Todd (Midwife)
A Patient Experience Perspective

I have been privileged enough to experience home births with both of my children in 2018 and 2021. The aftercare differed greatly; with my son in 2018, the majority of postnatal care then took place in the stand-alone midwifery-led unit in a clinic setting, including NIPE, day 5 blood-spot screening and discharge to the health visitor. Although this was the standard of care at the time, the difference in having these appointments at home was vast. With my daughter, due to the COVID-19 pandemic, I was able to stay in my own home for all postnatal care including the NIPE. This meant that I didn't have to face trying to get myself and her ready to make appointment times, struggling to find a car parking space and other trivial things made worse with the discomfort of the immediate postnatal period. It seems illogical to have a home birth and then have follow-up care in a hospital setting. I think that offering the NIPE examination in the home is greatly beneficial to mothers and alleviates time-pressures faced by midwives working in a clinic set-up.

THE NEWBORN INFANT PHYSICAL EXAMINATION: ADVANCING MIDWIFERY PRACTICE

The aim of the NIPE is to reduce morbidity and mortality by identifying congenital abnormalities[3] that have been detailed in this series. The NIPE is initially performed within 72 hours of birth and repeated at 6 to 8 weeks of age.[3] With the first examination occurring in the time frame that a woman will still be receiving midwifery care it is logical that this be performed by a midwife. Historically, the NIPE was undertaken by junior paediatric and neonatal medical staff. However, the development of post-registration training for midwives in 1995 and published standards and guidelines in 2008 have led to increased numbers of midwives performing the NIPE.[4] Following this, a small number of forward-thinking universities began to incorporate both NIPE theory and practice into the undergraduate programme as the benefits of midwives undertaking the NIPE became more recognised. More recently, since 2019 NIPE training has been incorporated into midwifery education standards.[5] This means that our future midwifery workforce will have the skills to perform the NIPE which will further advance the role of the midwife, whilst reducing the need for neonatal and paediatric colleagues to undertake the examination on "low risk" babies. Furthermore, by having increased numbers of midwives with this additional skill, maternity services will be able to provide a more seamless service with the benefits of midwives performing the NIPE including a greater provision of continuity of care and a reduction in waiting times for the NIPE to be performed.[6]

CONTINUITY OF CARER: FRIEND OR FOE

In the five years since the publication of Better Births[1] the main focus of the majority of maternity services has been to 'introduce' continuity of carer teams. There is no denying that there has been strong opposition from within the midwifery profession to the introduction of dedicated teams designed to provide continuity of carer. Furthermore, it has been identified that midwives are not able or willing to work in continuity models.[7] It could be argued that the opposition of midwives to working in continuity of carer models is due to the wider factors currently affecting maternity services such as the shortage of midwives rather than the concept.

It has been reported that eight out of ten midwives believe that that there are not enough staff to operate a safe service.[8] Therefore, until there is much-needed investment in maternity services to address concerns such as staffing the success of continuity of carer will remain limited. Furthermore, conflicting messages may affect the willingness of midwives to provide care in this way with support for continuity of carer being withdrawn by the Royal College of Midwives who now support the postponement or temporary suspension of continuity of carer teams.[9] This is contrast with the Nursing and Midwifery Council The Code "always practise in line with the best available evidence".[10] The physical benefits to women who receive continuity of carer are widely known, one consideration that is often overlooked in favour of some of the more impressive benefits is that a birthing person is more likely to be satisfied with their care.[11] Therefore, it would be beneficial for women to have the NIPE performed by a known a trusted care-giver whether that is a midwife from a continuity of carer team, their community midwife or the midwife from the birth.

Dayna Wright, Team Leader for Home Birth and Continuity of Carer
A Team Leader Perspective

As midwives who work for a home birth team, our whole ethos surrounds holistic care, continuity of care and care in the home environment. It is no different for the newborn and infant physical exam (NIPE), which is usually performed at the primary visit on day zero or day one. This protects the family bubble, increases service user satisfaction and reduces the chance of missed appointments at the hospital NIPE clinic in the first 72 hours following birth.

One of the many benefits of doing a NIPE at home with a family cared for by the home birth team is that the family history, birth history and any risk factors are already known. It is still important to gain a history from the family, including any family history of congenital heart, eye, hip or testes conditions.

Around 80% of the midwives working in the team are trained in doing NIPEs. It is a desired criteria on the job specification, but not essential. This is because we are still able to offer funded training through the Trust for those coming from other Universities and Trusts. The newly-qualified midwives from Birmingham City University will be trained as part of their undergraduate course which is a fantastic skill to have and consolidate during the preceptorship programme.

THE POSTNATAL JOURNEY: "WE HAVE ALWAYS DONE IT THIS WAY"

Postnatal services are often referred as the 'Cinderella' of maternity due to a combination of both reported poor experience by women and an unchanged maternal mortality rate in the postnatal period.[12,13] For women who birth in hospital, postnatal care will be provided in a ward environment with only a small number of women opting for an early postnatal transfer home. Depending on the woman and her baby's risk status and mode of birth, care may include observations, medical reviews and infant feeding support. However, delays for women who are suitable for transfer back to community care usually arise whilst awaiting the NIPE. It could be argued that midwives feel that it is in a woman's best interest to remain as inpatients whilst awaiting this examination as it may seem illogical to transfer a woman home to then return for an outpatient NIPE. Furthermore, some maternity services may not be structured to facilitate an outpatient NIPE service. This can in turn lead to frustration for both women and midwives, as women may wish to return home and commence family bonding and midwives may unfortunately have to respond to women voicing discontent with services. Some services are yet to update local guidelines with current national guidance whereby there is no lower limit to when the NIPE can be performed, with some services suggesting a six or twelve hour wait for the examination, further delaying transfers back home.

It is crucial that maternity services focus on improving the postnatal journey to reduce any potential for negative experiences and the impact this can have on maternal mental health. Maternity services need to move away from phrases such as "we have always done it this way" and remember to put the woman and her family at the centre of care. By encouraging and supporting early transfers home for women who are suitable maternity services may notice a reduction in complaints related to postnatal care and overloaded postnatal wards. Maternity services looking to offer early transfer home should devise a suitability criteria as outlined in *Table 1*. Neonatal pulse oximetry is a screening test that improves detection of congenital heart defects and infection.[14,15] Although this screening is not currently performed in all maternity units nationally, the introduction of this simple test could further reassure midwives undertaking early transfers home as it is an objective measure to add to the overall clinical assessment of the baby.[14] Follow-up could then be arranged depending on the woman's preference and incorporating the concept of care close to home, whether this is a community hub or the woman's home. Therefore, it could be argued that community or continuity midwives are best placed to undertake the NIPE.

> *"It has been reported that eight out of ten midwives believe that that there are not enough staff to operate a safe service.[8] Therefore, until there is much-needed investment in maternity services to address concerns such as staffing the success of continuity of carer will remain limited."*

Table 1*: Suitability Criteria for Early Transfer Home Following Birth

Suitability Criteria for Early Transfer Home Following Birth*	
• Minimum time for transfer home following birth >2 hours. • Ideally avoid transfer home between 22:00 – 08:00. • Gestation >37 weeks. • No adverse medical history. • Offer neonatal pulse oximetry screening at two or more hours of age prior to transfer home.	
Contraindications arising from labour*	**Contraindications arising from birth***
• Significant meconium stained liquor. • Prolonged rupture of membranes >18 hours. • Antenatal diagnosis of Group B Strep. • Maternal pyrexia or screened for sepsis. • Any known maternal and/or fetal risk factors. • Eclampsia.	• Caesarean birth. • Instrumental birth. • Epidural. • 3rd/4th degree tears. • Low birth weight <2.5kg. • Neonatal hypothermia. • Neonatal hypoglycaemia. • Neonatal hypoxia (Apgar <7 at 5 minutes and/or cord pH <7.05 arterial or <7.01 venous). • Neonatal birth trauma. • Shoulder dystocia. • Undiagnosed fetal anomaly. • Cord prolapse. • Postpartum Haemorrhage.

*Not an exhaustive list

Cathy Green, Home Birth Midwife and NIPE Practitioner

A NIPE Practitioner Perspective

As a home birth midwife and NIPE practitioner I often undertake the NIPE examination at home. I feel this is an integral part of the home birth service our midwifery team provides. Families can remain at home following their home birth, with a visit the following day to complete the NIPE. This ensures a salutogenic approach to the examination, removing the need for a hospital visit and allowing the whole family to be involved. A relaxed environment allows the parents to spend as much time as they need discussing any concerns and allows the midwife to assess family dynamics, to observe siblings, offer information and ask relevant questions in a calm space which all contribute to a more thorough NIPE assessment.



RECOMMENDATIONS FOR PRACTICE

- Maternity services to support NIPE practitioners to undertake the NIPE within a woman's home.
- Where possible for the NIPE to be performed by a known care giver to support continuity of carer which will increase the woman's experience and job satisfaction of the midwife.
- Maternity services to support and encourage early transfer home for women where possible.
- Maternity services to incorporate neonatal pulse oximetry screening as routine postnatal care which will aid detection of congenital heart defects and reassure midwives who support women who wish for an early transfer home.

CONCLUSION

The benefits of trained midwives undertaking the NIPE are clear and they are supported by a strong evidence base. The NIPE is an essential component of postnatal care and the location of this assessment can either positively or negatively impact a woman's postnatal experience. Furthermore, a wider view is required by maternity services looking to improve the postnatal journey for women and families and consideration is required as to whether routine admission to postnatal wards is advantageous for both women and maternity services. **TPM**

ACKNOWLEDGEMENTS

Grateful thanks to Maggie Prain for comments, suggestions and NIPE wisdom. Furthermore, my thanks to the wider NIPE team at Birmingham City University for asking me to participate in this important and much-needed series.

REFERENCES

1. NHS England. National Maternity Review: Better Births Improving outcomes of maternity services in England A Five Year Forward View for maternity care. https://www.england.nhs.uk/wp-content/uploads/2016/02/national-maternity-review-report.pdf. Published 2016. Accessed September 25, 2021.

2. NHS England. NHS Improvement. Better Births Four Years On: A review of progress. https://www.england.nhs.uk/wp-content/uploads/2020/03/better-births-four-years-on-progress-report.pdf. Published 2020. Accessed September 25, 2021.

3. Public Health England. Newborn and infant physical examination (NIPE) screening programme handbook. https://www.gov.uk/government/publications/newborn-and-infant-physical-examination-programme-handbook/newborn-and-infant-physical-examination-screening-programme-handbook. Updated April 28, 2021. Accessed September 29, 2021.

4. Hempstock J, Samanta S. Routine examination of the newborn – development of a fully midwifery-led service. *Infant Journal*. 2011;7(2);49-51.

5. Nursing and Midwifery Council. Part 3: Standards for pre-registration midwifery programmes. https://www.nmc.org.uk/globalassets/sitedocuments/standards/standards-for-pre-registration-midwifery-programmes.pdf. Published November 18, 2019. Accessed September 29, 2021.

6. Hayes J, Dave S, Rogers C, Quist-Therson E, Townsend J. A national survey in England of the routine examination of the newborn baby. *Midwifery*. 2003;19(4):277-284. doi:10.1016/s0266-6138(03)00044-5.

7. Taylor B, Cross-Sudworth F, Goodwin L, Kenyon S, MacArthur C. Midwives' perspectives of continuity based working in the UK: A cross-sectional survey. *Midwifery*. 2019;75:127-137. doi:10.1016/j.midw.2019.05.005.

8. Royal College of Midwives. Fears for maternity as staffing shortages hit safety and morale says RCM. https://www.rcm.org.uk/media-releases/2020/november/fears-for-maternity-as-staffing-shortages-hit-safety-and-morale-says-rcm/. Published November 16, 2020. Accessed October 02, 2021.

9. Walton G on behalf of the Royal College of Midwives. Letter to Jacqueline Dunkley-Bent. https://pre.rcm.org.uk/media/5259/letter-to-j-dunkley-bent-august-2021-rcm-response-to-staff-shortages.pdf. Published August, 2021. Accessed September 30, 2021.

10. Nursing and Midwifery Council. The Code: Professional standards of practice and behaviour for nurses, midwives and nursing associates. https://www.nmc.org.uk/globalassets/sitedocuments/nmc-publications/nmc-code.pdf. Accessed October 02, 2021.

11. Sandall J, Soltani H, Gates S, Shennan A, Devane D. Midwife-led continuity models versus other models of care for childbearing women. *Cochrane Database Sys Rev*. 2016;28;4(4). Accessed September 30, 2021. doi.org/10.1002/14651858.CD004667.pub5.

12. Royal College of Midwives. Postnatal services are the Cinderella of maternity services say midwives. https://www.all4maternity.com/postnatal-services-cinderella-maternity-services-say-midwives/. Accessed October 03, 2021.

13. Macdonald C, Sharma S, Kallioinen M, Jewell D. Postnatal care: new NICE guideline for the 'Cinderella service'. *Br J Gen Pract*. 2021;71(710):394-395. doi:10.3399/bjgp21X716825.

14. Cawsey MJ, Noble S, Cross-Sudworth F, Ewer AK. Feasibility of pulse oximetry screening for critical congenital heart defects in homebirths. *Arch Dis Child Fetal Neonatal Ed.* 2016;101: 349-351. doi:10.1136/archdischild-2015-309936.

15. Ismail AQT, Cawsey M, Ewer AK. Newborn pulse oximetry screening in practice. *Arch Dis Child Educ Pract Ed*. 2017;102:155-161. doi:10.1136/archdischild-2016-311047.

Chapter summary

Key learning points

DECOLONISING MIDWIFERY EDUCATION PART TWO:

NEONATAL ASSESSMENT

> AUTHORS

All authors from Leicester School of Nursing and Midwifery, De Montfort University



Dr Diane Ménage
Senior Lecturer, Midwifery
Twitter @Dianethemidwife



Maxine Chapman
RM, Senior Lecturer, Midwifery, and Fair Outcomes Champion: Decolonising DMU Project, De Montfort University
Twitter @maxinevchapman



Maureen Raynor
Senior Lecturer, Midwifery
Twitter @raynor_maureen



Zaheera Essat
Lecturer, Midwifery
Twitter @ZaheeraEssat



Rachel Wells
Senior Lecturer and Programme Lead, Midwifery
Twitter @Rachmwells



SUMMARY

Assessment of the skin is an important element of neonatal examination. Therefore, midwives need to develop knowledge and skills in this area to recognise changes in the skin and understand what these signify. Historically, teaching in this area has been skewed towards changes seen in newborns with light skin tones, resulting in a gap in clinical knowledge and resources on the assessment of skin in newborns with darker skin tones. This second article, on the decolonisation of midwifery education and practice, focuses on clinical assessment of the skin when examining newborns.

***NB we have sourced images via stock websites and from the generous public, to whom we are grateful for supporting this important work of decolonising the curriculum.**

INTRODUCTION

Midwives have an important role in the assessment of neonates to confirm normality, detect deviations from the norm and arrange appropriate referral. Midwives examine neonates at birth, at postnatal examinations and when performing the Newborn Infant Physical Examination (NIPE). Historically, very little attention has been paid to the significance of skin colour when teaching midwives examination skills and there is a knowledge gap around the detection of clinical signs on darker skins. There has been a lack of awareness that many skin conditions can be more difficult to recognise on darker skins, and almost all clinical textbooks use examples and illustrations of people

with pale skins. Generations of clinicians have been educated in this way and it is only very recently that this gap in clinical education has been recognised and is now being addressed.[1] Neonatal skin conditions are no exception to this knowledge gap. This is the second of two articles on skin assessment in maternity care, which seek to kickstart the discussion and begin to fill that knowledge gap, plus raise awareness of some of the clinical signs and features that present differently, on darker skin tones. The first article, also published in this issue, focused on enhancing knowledge and comprehension of the nuances involved in assessing women with dark skin tones, while this article discusses the nature of neonatal skin colour, assessment of the baby at birth, signs of cyanosis, skin conditions, birthmarks and neonatal jaundice. A clinical vignette and critical questions are intended to encourage readers to consider this example and reflect on their own experiences when assessing the health and wellbeing of babies with skin tones other than white.

SKIN COLOUR

Skin colour in the neonate is influenced by a number of physiological factors: the density and distribution of melanin (a dark pigment which provides protection from ultra-violet rays in sunlight); haemoglobin; bilirubin and skin thickness.[2] Therefore, ethnicity, general health and gestational age will all be significant factors. Although we may think of ethnicity as the main determinant of skin colour, studies have shown that skin tone and ethnicity do not always correlate precisely.[3] Skin tone varies among individuals from any given ethnic group. Therefore, it is not necessarily accurate or useful to talk about African skin or Asian skin. In fact, there is huge variety in skin colour and yet clinical textbooks on assessment of the skin are almost exclusively focused on pale skin tones. Few studies have explored this topic, although there have been recent attempts to classify neonatal skin colour.[3] However, neonatal skin is relatively dynamic as babies are often born slightly paler than their parents; their skin colour developing in their first weeks or months and beyond as their skin is exposed to the natural light.[3] Neonates also have areas that contain less pigment – for example, the palms of the hands – while other areas may be more pigmented – for example, the genitals, with a deeply pigmented scrotum being a common incidental finding in Black, Asian and Middle Eastern baby boys.[4]

GENERAL ASSESSMENT OF THE BABY AT BIRTH

Visual assessment of the skin is an important part of neonatal clinical examination and any assessment must be made in relation to individual skin tone in order to confirm normality and identify abnormalities. For the midwife, examining the baby following birth using the APGAR score provides a system for rapidly assessing newborn health using five criteria: heart rate, respiratory effort, tone, reflex and skin colour.[5,6] The newborn is scored (out of two) for each criterion, usually at one minute and at five minutes, allowing a maximum score of 10. However, assessment of colour is known to be the most problematic and least reliable field, because to score two the baby needs to be 'pink all over'. As a screening tool for detecting babies who are compromised, this description is

> *"There has been a lack of awareness that many skin conditions can be more difficult to recognise on darker skins, and almost all clinical textbooks use examples and illustrations of people with pale skins"*



> *"Skin tone varies among individuals from any given ethnic group. Therefore, it is not necessarily accurate or useful to talk about African skin or Asian skin"*

> *Midwives have an important role in the assessment of neonates to confirm normality, detect deviations from the norm and arrange appropriate referral*



> *The teaching of clinical assessment of the newborn must be relevant and fit for purpose for all newborns, whatever their skin tones*

particularly problematic. Some babies with darker skin tones may be well perfused but will not look particularly pink, making it practically impossible for them to gain maximum score in this field. This is of concern because it means that darker-skinned babies may be given inaccurate APGAR scores, which could lead to unnecessary surveillance and interventions for the baby and increased anxiety for the parents. Similarly, it may be harder to assess 'blueness' in the skin of a Black or Brown-skinned baby and this could lead to inadequate detection of those babies who are compromised. Therefore, there is a strong argument for reviewing and developing the APGAR scoring system to ensure that it is fit for purpose for all neonates.

ASSESSING FOR CYANOSIS IN THE NEONATE

Cyanosis is the blue discolouration of the skin and mucous membranes caused by deoxygenated haemoglobin.[7] In neonates peripheral cyanosis is common in the first 24 hours of life and is not considered pathological if the baby is generally well.[8] Central cyanosis is associated with pathology and can indicate respiratory, cardiovascular or haematological abnormalities.[9] Therefore, it is essential that midwives are able to detect signs of cyanosis in neonates. As a fundamental skill in midwifery practice, teaching has been impaired by language and assumptions about skin colour. It has been the norm to talk of skin looking blue, white or 'pinking up' and, although this may reflect what is seen in paler-skinned neonates, it may not describe what happens in babies with darker skin tones. For this reason, we would strongly advocate moving away from this language and emphasise that the assessment of cyanosis should assess for any grey or blue discolouration of the skin (*see Picture 1*). It should always involve examination of the lips and mucous membrane in the mouth and tongue because these are areas where there is thin epidermis and a good blood supply in all skin colours and therefore sites that are reliable indicators of central cyanosis.[1,7] Assessment of the nail beds is not useful for detecting central cyanosis in neonates under 24 hours of age, given that non-pathological, peripheral cyanosis may complicate the assessment.[8] While it is essential that midwives hone their observation and examination skills for babies of all skin colours, pulse oximetry provides an important objective measurement where there are concerns. Moreover, in many maternity units this is now offered routinely as part of newborn screening.[10]

***Picture 1* – Cyanotic newborn**



NEONATAL SKIN CONDITIONS

Rashes are common in neonates and therefore midwives need to be skilled at recognising normal, harmless conditions and those that may need to be referred. Erythema Toxicum Neonatorum (commonly called Newborn Rash) can look alarming but it is an insignificant, transient rash present in approximately half of babies in the first few weeks of life – *see Pictures 2 and 3.*[11] It can be more difficult to assess on darker skins as erythema (redness) may be less obvious.

***Pictures 2 and 3* - Erythema Toxicum Neonatorum**





Neonatal pustular melanosis is uncommon in white babies but is thought to affect around 5-15% of babies with Black parents.[12] It resolves spontaneously but similarly it can be very concerning for parents, particularly as the small pustules develop and then turn into flat, brown lesions (*See Picture 4).* Careful and comprehensive inspection is key and listening to parents is important because they will often be the ones to notice subtle marks and blemishes.

Picture 4 – Neonatal pustular melanosis



BIRTH MARKS

Dermal melanocytosis (also slate grey nevus or blue spot) are blue/grey or brown patches found on newborn babies. They are a type of birth mark seen on babies of all skin tones, although they are very common in dark-skinned babies and present in up to 90% of babies from Black and Asian ethnicities.[11] They are usually present from birth and found on the buttocks or lower back and they generally disappear in the first few years of life.[11] *See Pictures 5 and 6* overleaf. Although often referred to as *Mongolian blue spot*, this description is an inaccurate and outdated term based on discredited race theories.[13] For this reason we strongly recommend using the correct name: *dermal melanocytosis* or simply *blue spot*. Inability to accurately recognise blue spot has led to this being confused with bruising. Sadly, this has sometimes resulted in inappropriate child protection referrals, causing unnecessary distress to families.[14] It is important that midwives record all birth marks and skin lesions on the body map and in all neonatal records as soon as it is noticed and continue to observe and document any changes. While remaining vigilant to the possibility of bruising from birth trauma or inflicted harm, midwives can differentiate between bruising and blue spot if they understand the distinguishing features of each. Blue spot predominantly appears at typical sites (buttocks and back), they are patches of skin that may look blue/grey or, on dark-skinned babies, they may just look darker than the surrounding skin. They are more uniform in colour and they do not change colour.[1] They are always non-tender with no associated swelling or redness. Bruises may be tender with associated inflammation. They can be blue/grey but they are less uniform in colour and the colour also changes as the bruise ages; sometimes purple and yellow tones can be seen.[15] The head-to-toe examination following birth and during each neonatal examination plays a vital role in detecting bruising.

***Pictures 5 and 6* – Blue spot**





JAUNDICE

Jaundice is the yellow colouration of skin and sclera caused by raised bilirubin (a bile pigment) in the circulation.[16] Neonatal jaundice affects 60% of term babies and 80% of preterm babies in the first week of life.[16,17] In most cases, this is a physiological jaundice that spontaneously resolves without treatment. Less commonly, jaundice is pathological and can be life-threatening. Observation and examination of newborn babies to detect those babies who may have pathogenic jaundice and require referral is an important part of neonatal care.[17] Measurement using a transcutaneous bilirubinometer is recommended practice in the UK, in babies with suspected or obvious jaundice,[16,17] although it is not always available, particularly in community settings. Therefore, visual assessment is still a key aspect of assessing the degree of neonatal jaundice. This can be more difficult in babies with dark skin tones – *see Pictures 7-9*.[18] A full visual assessment should be made in good light and particular attention should be paid to inspecting the whites of the eyes (sclera), gums, palms of the hands and small areas of skin temporarily 'blanched' by light digital pressure.[17,19]

***Pictures 7-9* – Neonatal jaundice**







Again, listening to the parents is also key. They may notice changes in skin colour that are not evident to a midwife who has not seen the baby before or who lacks knowledge and experience in assessing babies with darker skins. In the vignette below, a midwife reflects on a neonatal examination of a baby with white and Afro-Caribbean heritage in relation to detection of jaundice. After reading this, use the critical questions to reflect on current practice.

A REFLECTION ON JAUNDICE ASSESSMENT OF A NEWBORN WITH WHITE AND AFRO-CARIBBEAN HERITAGE

As a community midwife, I attended a primary home visit with a final-year student midwife, to a mother who had given birth to her third baby on the previous day following an uncomplicated pregnancy and birth. The parents' ethnicities were that of white and Afro-Caribbean heritage, the student was white and my heritage is white and Afro-Black Caribbean. During the assessment of the newborn, the student had asked me if I agreed that the newborn appeared to be jaundiced. I reassured her that the newborn was not jaundiced based on a full assessment. A discussion followed wherein the mother shared her experiences with us of the care and assessment of her first two babies when they were considered to be jaundiced during the initial postnatal period. The mother expressed that she considered the additional surveillance visits undertaken by the midwives to be unnecessary because results of the investigations were found to be within the normal ranges. Care provided with her first newborn included a referral to the hospital because there was not a transcutaneous bilirubinometer (TCB) available for the community midwife to use during the visit. The findings of the TCB were within the normal range and therefore no further intervention was necessary. The mother expressed her frustration as she felt that her newborns were healthy and that perhaps the midwives and other healthcare professionals involved were not familiar with the healthy skin tones for babies with white and Afro-Black Caribbean heritage. I felt that the commonality that we shared in our heritage enabled the mother to be open with me about her experiences. The discussion we had highlighted limitations of individualised assessment of jaundice in the newborn, because of a lack of knowledge around jaundice in neonates with skin tones that were other than white. Reassurance was given to the mother and advice provided on monitoring the health and wellbeing of her newborn. Following the visit, the student midwife expressed her concern that she had limited knowledge and experience of the assessment of babies with skin tones that were not white, which she felt would lead her to undertake a TCB or make a referral to be 'safe'.

CONCLUSION

The teaching of clinical assessment of the newborn must be relevant and fit for purpose for *all* newborns, whatever their skin tones. Images of newborn babies with dark skin tones should be included in textbooks and other educational materials. Resources, such as clinical manikins, should reflect a range of skin tones. Those working in midwifery education have a responsibility to ensure that what is taught is relevant and appropriate for mothers and babies of all skin tones. **TPM**

PRACTICE POINTS

Jaundice in assessment of the neonate
Enhancing your learning: explore images of jaundice in a diversity of skin tones.

History
- Is an interpreter required?
- Listen to the mother: are there any concerns with the colour of the skin, feeding, activity or any other concerns?

Observation
- Ensure you have ambient lighting during the assessment process. Where possible use natural light or a halogen light source, as estimation of the degree of jaundice can be inaccurate due to the type of lighting and the reflective ability of surrounding objects.
- Ensure you have fully undressed the newborn for the assessment to fully visualise the colour of the skin – face, abdomen, back and limbs and palms of the hands.
- Ensure 'top to toe' examination is performed with a specific focus on:
  - General behaviour
  - Eyes – assessing the colour of the sclera
  - Mouth – assessing the colour of the gums
  - Nappies – observe for yellow or darker-stained urine.

Investigation
- Ensure full explanation to parents and gain consent if further investigation is required
- Where jaundice is suspected, ensure investigations are implemented, results followed up and referrals made as appropriate.

Documentation
- Ensure findings of the assessment are accurately documented.

REFERENCES

1. Mukwende M, Tamony P, Turner M. Mind The Gap: A handbook of clinical signs in black and brown skin. Published 2020. Accessed November 11, 2020.

2. Anbar T, Eid A, Anbar M. Evaluation of different factors influencing objective measurement of skin color by colorimetry. Skin Res Technol. 2019;25(4):512-516.

3. Maya-Enero S, Candel-Pau J, Garcia-Garcia J, Giménez-Arnau A, López-Vílchez M. Validation of a neonatal skin color scale. Eur J Pediatr. 2020;179(9):1403-11.

4. Ogilvy-Stuart A, Midgley P. Pigmented Scrotum. Practical neonatal Endocrinology: Cambridge Clinical Guides. UK: Cambridge University Press; 2006: 79-82.

5. Apgar V. Proposal for a new method of evaluation of newborn infants. Anaesthesia and Analgesia. 1952;32:260-267.

6. NICE. Intrapartum care for healthy women and babies; Clinical Guideline (CG190). https://www.nice.org.uk/guidance/cg190. Updated February 2017. Accessed January 24, 2021.

7. Innes J, Dover A, Fairhurst K, Macleod J. Macleod's clinical examination. 14th ed. Edinburgh: Elsevier; 2018: 28.

8. Ransome H, Marshal J. Recognising the healthy baby at term through examination of the newborn screening. In: Marshall J, Raynor M eds. Myles Textbook for Midwives. 17th ed. Edinburgh: Elsevier; 2020: 932-994.

9. Vargo L. Cardiovascular Assessment. In Tappero E, Honeyfield M, eds. Physical assessment of the newborn: a comprehensive approach to the art of physical examination. 5th ed. New York: Springer Publishing Company; 2017.

10. Winter G. Pulse oximetry screening. British Journal of Midwifery. 2020;28(2):86-87.

11. Mancini A, Krowchuk D, Bruckner A et al. Pediatric Dermatology: A Quick Reference Guide. Elk Grove Village, Chicago: American Academy of Pediatrics; 2016.

12. Ghosh S. Neonatal pustular dermatosis: an overview. Indian Journal Dermatology. 2015;60(2):211.

13. Zhong C, Huang J, Nambudiri V. Revisiting the history of the "Mongolian spot": The background and implications of a medical term used today. Pediatric Dermatology. 2019;36(5):755-757.

14. Roberts E. Maria Miller refers campaign to Matt Hancock. Romsey Advertiser. https://www.romseyadvertiser.co.uk/news/basingstoke/18643981.maria-miller-refers-campaign-matt-hancock/. Published August 11, 2020. Accessed November, 11 2020.

15. Gupta D, Thappa D. Mongolian spots: How important are they? World J Clin Cases. 2013;1(8):230-232.

16. McIntyre J. Significant Problems of the Newborn baby. In: Marshall J, Raynor M, eds. Myles Textbook for Midwives. 17th ed. Edinburgh: Elsevier; 2020: 932-994.

17. NICE. Jaundice in newborn babies under 28 Days, Clinical Guideline. www.nice.org.uk/guidance/cg98. Updated October 2016. Accessed November 11, 2020.

18. Treadwell P. Paediatric Dermatology and the Ethnic Patient. In: Dadzie O, Petit A, Alexis A, eds. Ethnic Dermatology: Principles and Practice Hoboken. New York: John Wiley & Sons; 2013: 72.

19. Wan A, Mat Daud S, Teh S, Choo Y, Kutty F. Management of neonatal jaundice in primary care. Malaysian Family Physician. 2016;11(2-3):16-19.

Chapter summary

Key learning points